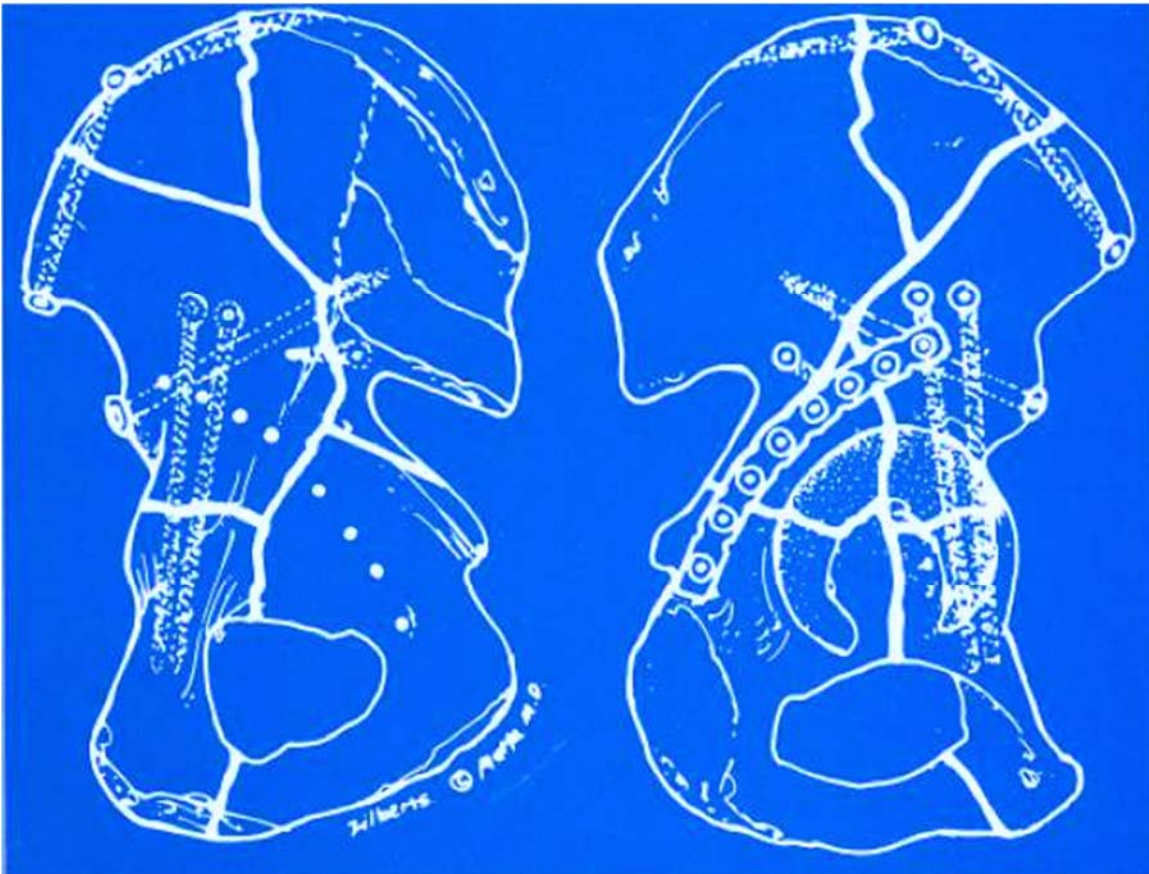


Surgical Approaches to Fractures of the Acetabulum and Pelvis



Joel M. Matta, M.D.

Sponsored by



APPROACHES TO THE ACETABULUM

No one surgical approach is applicable for all acetabulum fractures. After examination of the plain films as well as the CT scan the surgeon should be knowledgeable of the precise anatomy of the fracture he or she is dealing with. A surgical approach will be selected with the expectation that the entire reduction and fixation can be performed through the surgical approach. A precise knowledge of the capabilities of each surgical approach is also necessary. In order to maximize the capabilities of each surgical approach it is advantageous to operate the patient on the PROfx® Pelvic Reconstruction Orthopedic Fracture Table which can apply traction in a distal and/or lateral direction during the operation.

The table will also stably position the limb in a number of different positions.

KOCHER-LANGENBECK APPROACH

The Kocher-Langenbeck approach is primarily an approach to the posterior column of the Acetabulum. There is excellent exposure of the retroacetabular surface from the ischial tuberosity to the inferior portion of the iliac wing. The quadrilateral surface is accessible by palpation through the greater or lesser sciatic notch. A less effective though often very useful approach to the anterior column is available by manipulation through the greater sciatic notch or by intra-articular manipulation through the Acetabulum (Figure 1).

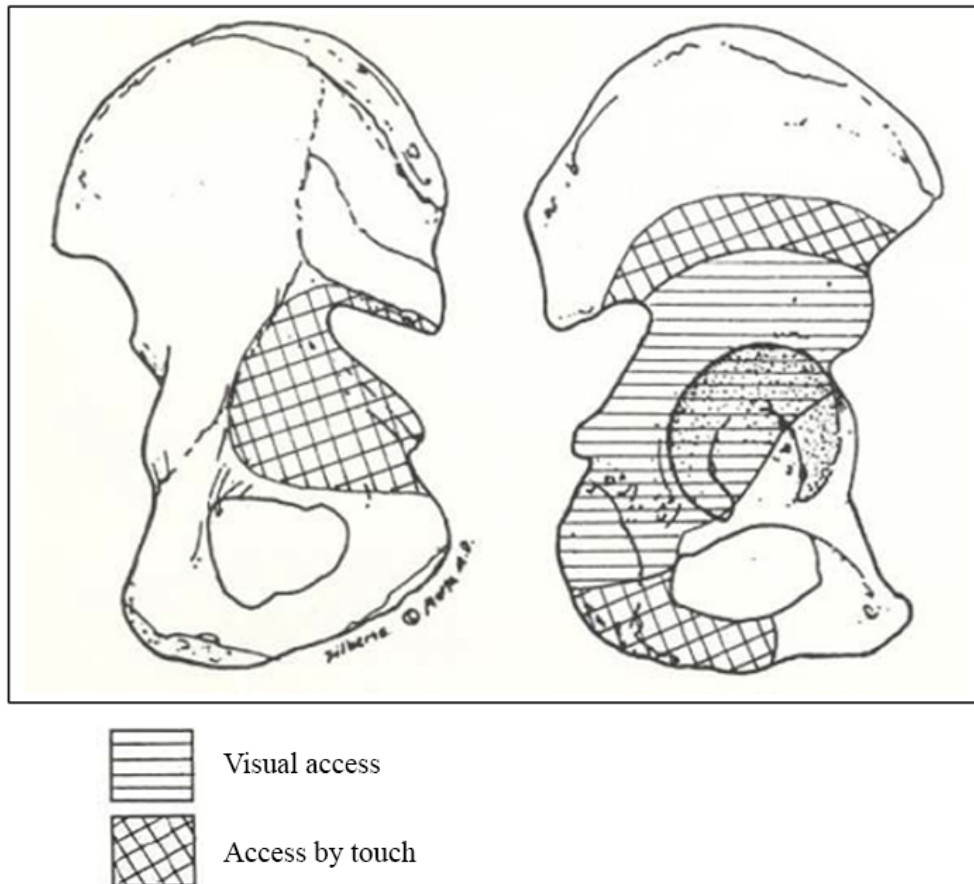


Figure 1. Access to the bone with the Kocher-Langenbeck Approach

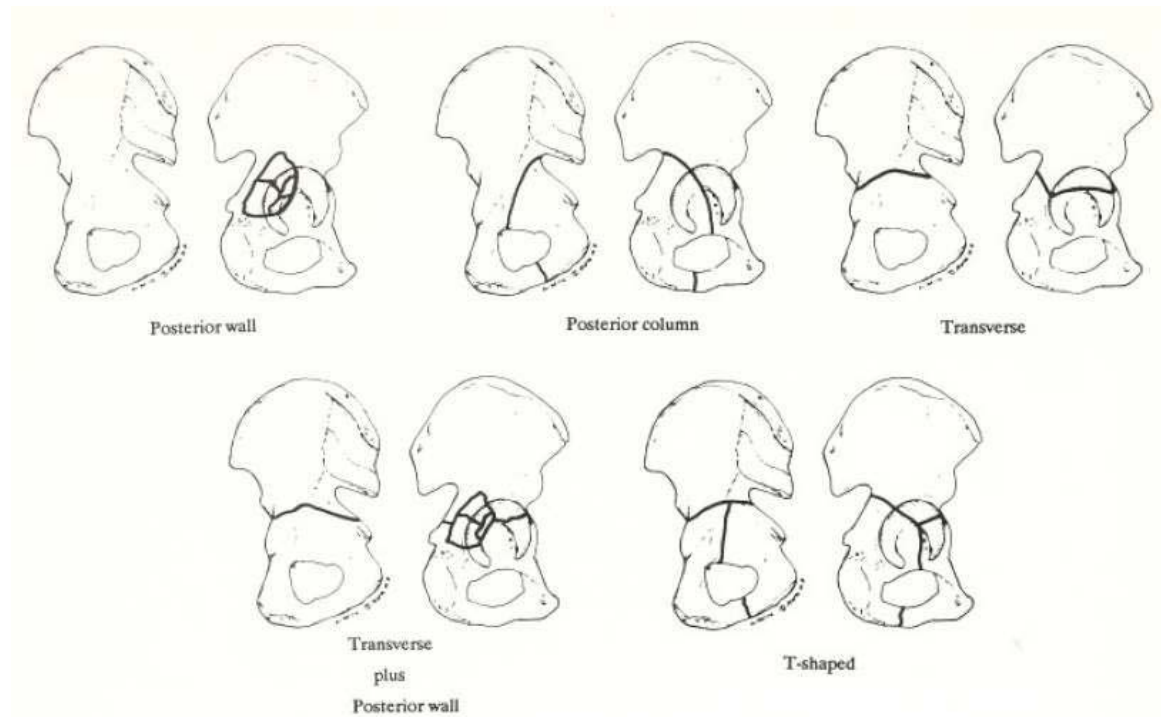


Figure 2. Fractures operated through the Kocher-Langenbeck approach.

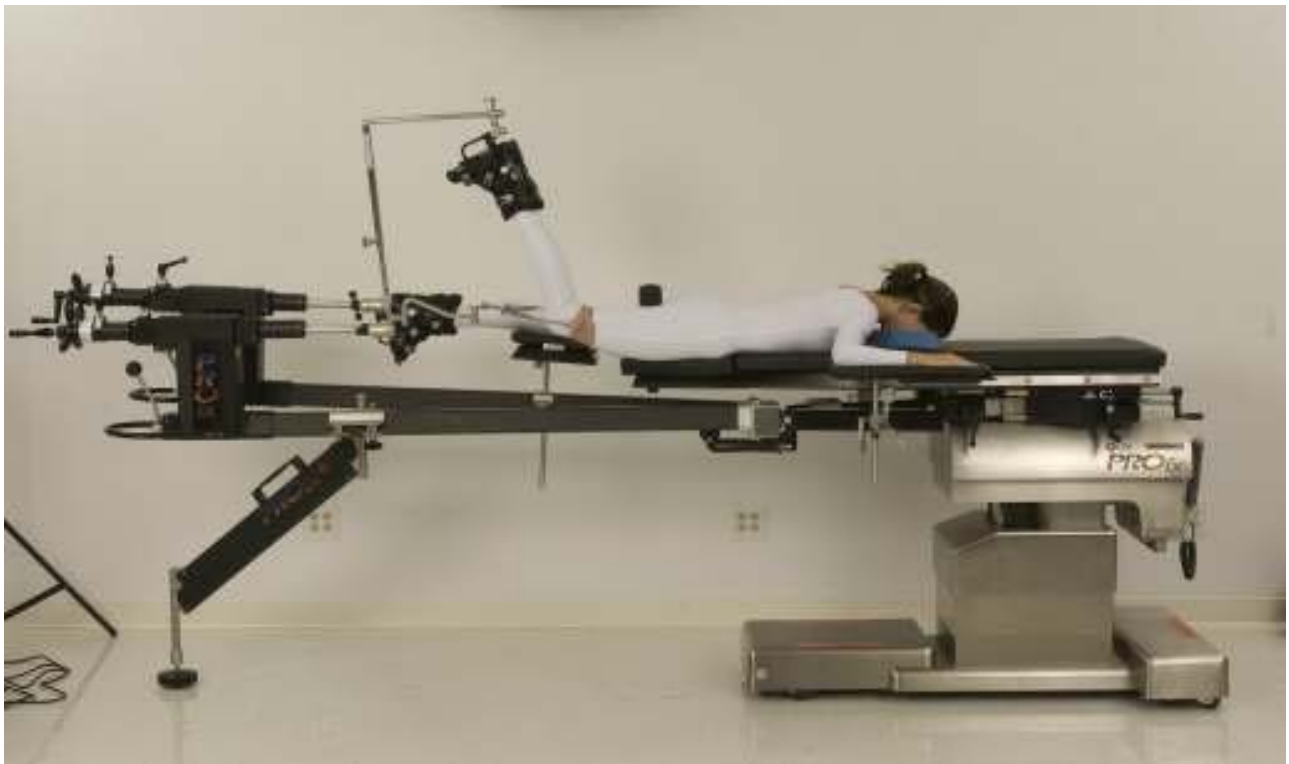


Figure 3. Positioning of the patient on the PROfx® Pelvic Reconstruction Orthopedic Fracture Table for operations through the Kocher-Langenbeck approach.

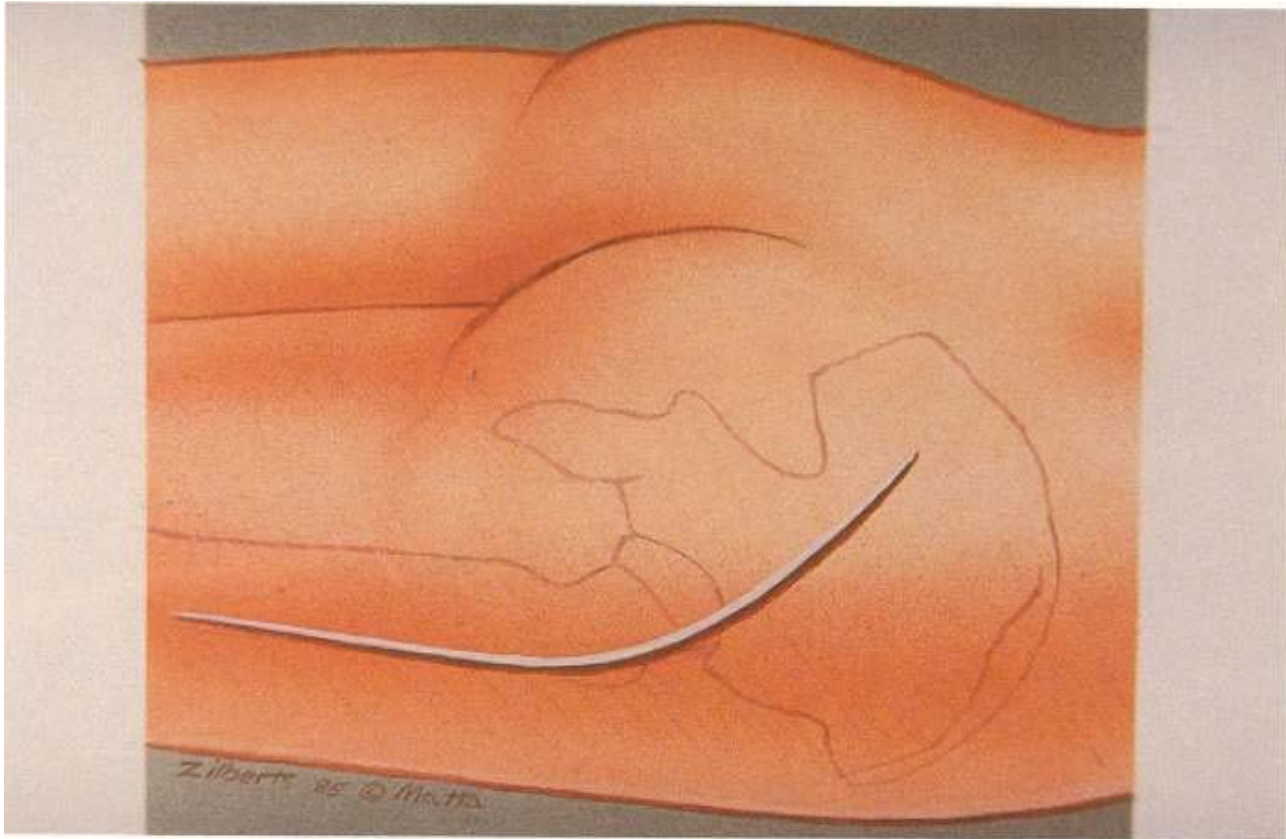


Figure 4. Skin Incision for the Kocher-Langenbeck approach.

The Kocher-Langenbeck approach is indicated for Posterior wall, Posterior column, transverse, transverse plus posterior wall, and some T-shaped fractures (Figure 2). It is indicated for old fractures of the posterior wall and posterior column.

Prior to beginning this approach a Foley Catheter is placed in the bladder. A transcondylar Steinmann pin is placed through the distal femur. The patient is placed in the prone position on the PROfx® Surgery Table with traction applied to the transcondylar Steinmann pin and the knee flexed at least 60 degrees (Figure 3).

The Incision starts about 5 centimeters lateral to the posterior-superior spine and extends anteriorly and distally to the greater trochanter and then distally along the thigh to approximately the mid-portion of the thigh (Figure 4).

The gluteal fascia and fascia lata are incised in line with the skin incision. The fibers of the gluteus maximus are split bluntly. The trochanteric bursa is incised. The gluteus maximus tendon is transected at its insertion on the posterior femur. The gluteus maximus should not be split too proximally or the fibers of the inferior gluteal nerve which lie within the muscle will be torn.

The sciatic nerve is normally located at this point at its position on the posterior aspect of the quadratus femoris. It is followed proximally across the posterior aspect of the obturator internus and gemellae to the point where it disappears beneath the piriformis muscle. A small vascular pedicle often crosses the posterior aspect of the nerve. In order to mobilize the nerve and see it fully this small vascular pedicle should be clamped,

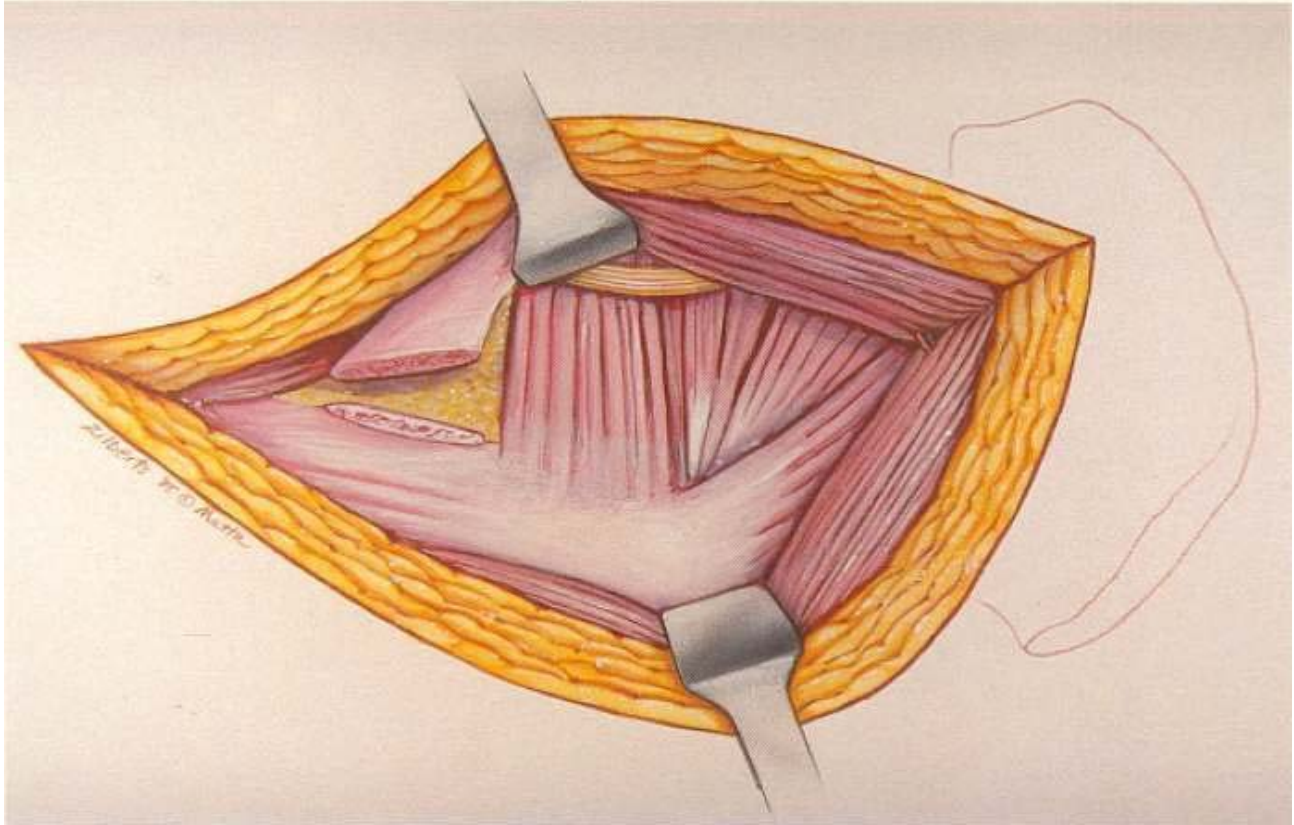


Figure 5. Splitting of the gluteus maximus muscle.

transected and cauterized (Figure 5).

The tendon of the gluteus medius is identified at its intersection on the trochanter. The gluteus medius muscle is retracted superiorly and anteriorly exposing the piriformis muscle and tendon. The piriformis tendon is tagged with suture and transected near its insertion on the greater trochanter. Reflection of the piriformis muscle posteriorly exposes the greater sciatic notch. Just below the insertion of the piriformis tendon is found the tendon of the obturator internus. The two gemellae lie superior and inferior to this tendon. A tag suture is placed through the tendon and the obturator internus tendon is transected along with the superior and inferior gemellae. The tendon and the gemellae are reflected posteriorly and medially, thereby exposing the lesser sciatic notch. The

obturator internus originates from the quadrilateral surface and passes through the lesser sciatic notch to its insertion on the femur. The lesser sciatic notch acts as a pulley for the tendon. A small bursa is present at the point where the tendon pulleys around the lesser sciatic notch. As this bursa is entered, the tendon of the obturator internus is clearly seen as well as the smooth cartilaginous border of the lesser notch. The tip of a retractor is placed into the lesser notch to retract the obturator internus as well as the sciatic nerve. A special sciatic nerve retractor is very useful in this area.

A periosteal elevator is used along the retroacetabular surface from the ischial tuberosity to the inferior portion of the ilium. The periosteal elevator can also be introduced into the greater sciatic

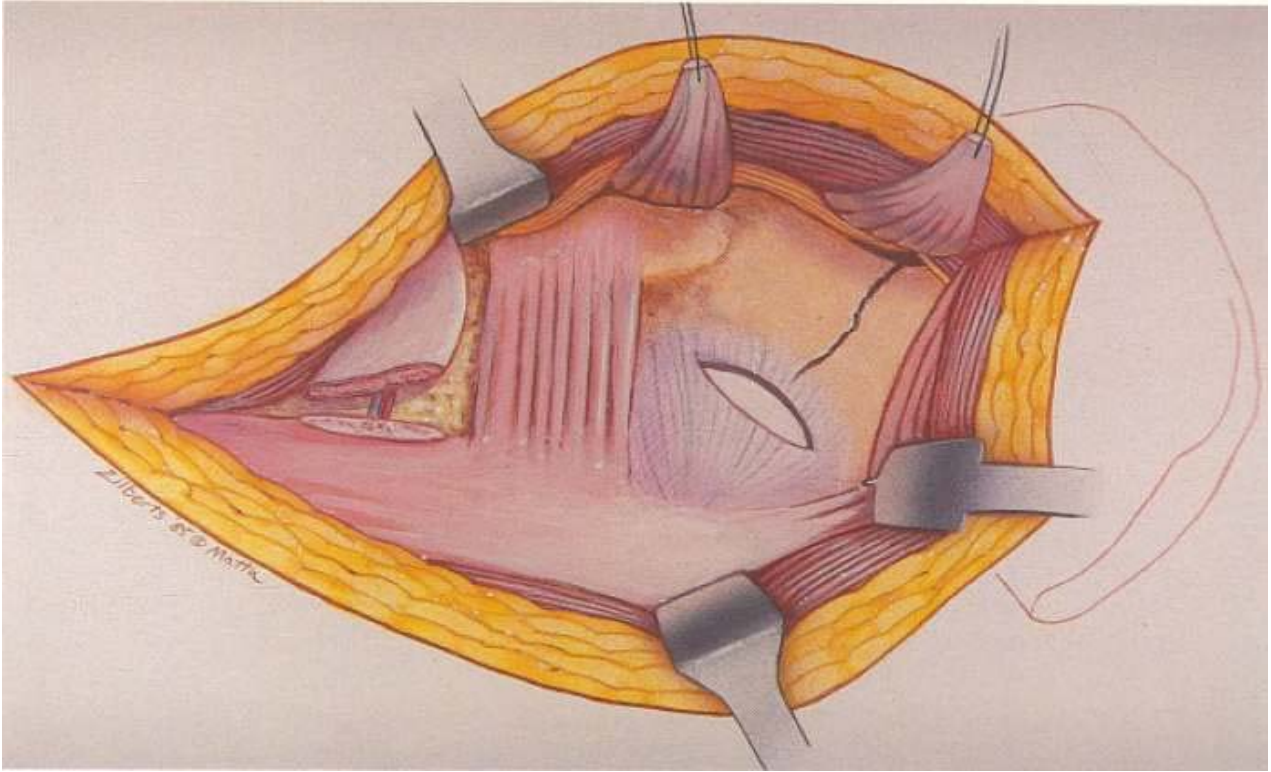


Figure 6. Completed exposure of the retroacetabular surface.

notch to clear periosteum and the obturator internus muscle from the quadrilateral surface. Palpation of the quadrilateral surface will then aid in fracture reduction. Another retractor can be placed with its tip in the greater sciatic notch. A Hohmann retractor is usually placed with its tip driven into the inferior portion of the iliac wing to retract the gluteus medius and minimus. A capsulotomy performed along the rim of the acetabulum will expose the acetabulum cartilage and femoral head (Figure 6). Further access to the inferior as well as anterior portion of the iliac wing can be obtained through a trochanteric osteotomy or a partial or complete transection of the gluteus medius tendon.

Care must be taken throughout the procedure to retract only gently on the sciatic nerve. After the retractors are placed in the lesser and/or greater

Sciatic Notch the nerve tension should be checked by palpation. Whenever maximal retraction is not necessary the assistant should relax tension on the retractors retracting the sciatic nerve. It is also possible to injure the superior gluteal nerve if the gluteus medius and minimus are retracted too vigorously in a proximal direction. The tension on the superior gluteal nerve can also be checked by palpation of the nerve just anterior to the greater sciatic notch.

At the completion of the procedure Hemovac drains are placed along the external ilium and as well in the greater sciatic notch. The tendons of the obturator internus, piriformis as well as gluteus maximus are reattached to the femur with suture at their anatomic position. If the tendon of the gluteus medius has been transected, this is also repaired.

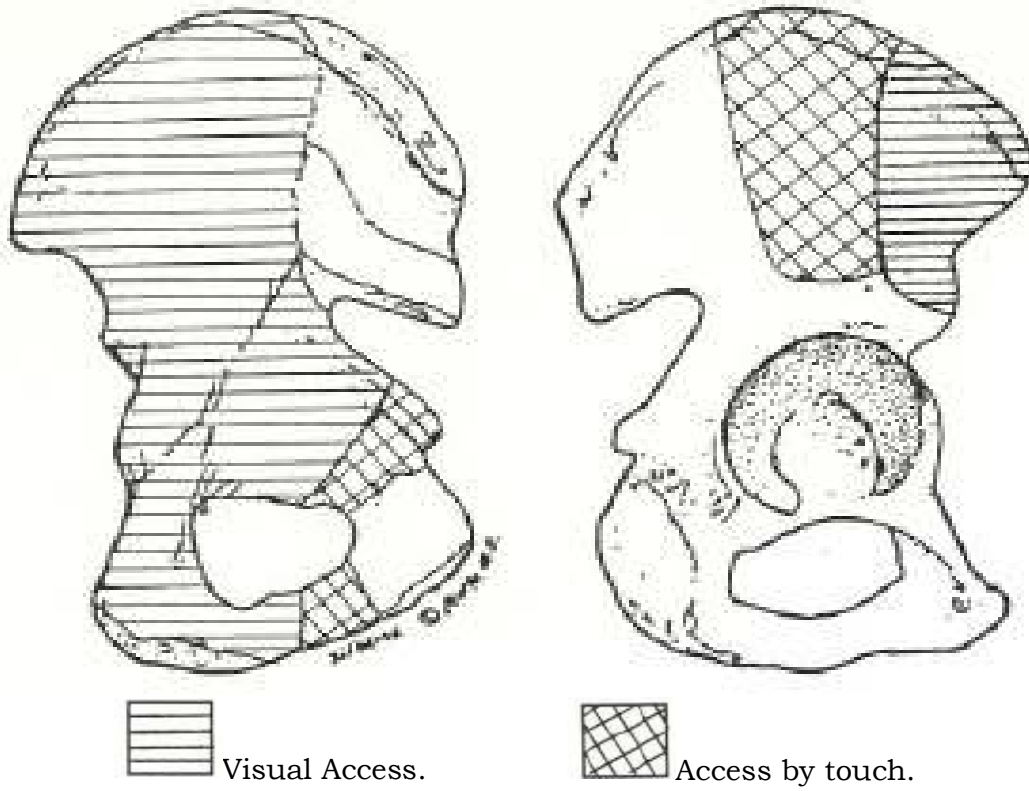


Figure 7. Access to the bone with the ilioinguinal approach.

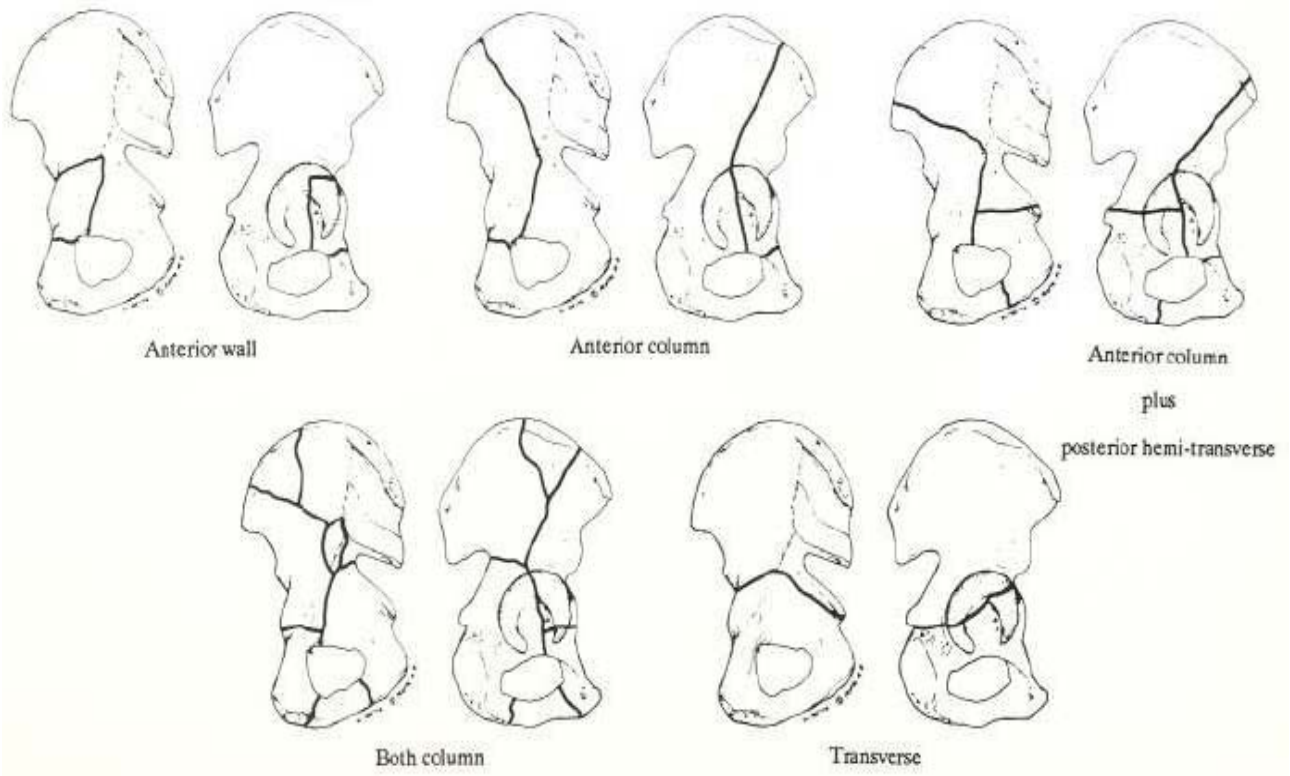


Figure 8. Fractures operated through the ilioinguinal approach.

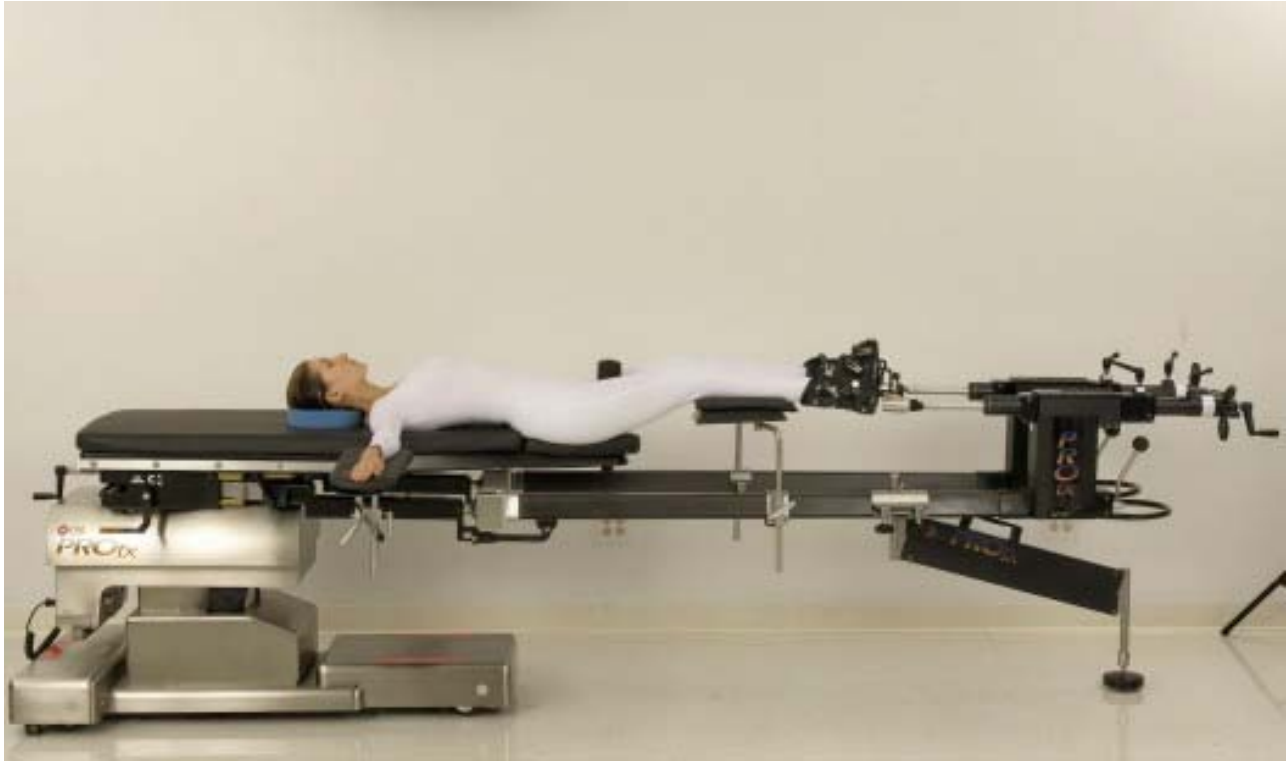

Figure 9. Positioning of the patient on the PROfx® Pelvic Reconstruction Orthopedic Fracture Table for operations through the ilioinguinal approach.

ILIOINGUINAL APPROACH

The ilioinguinal approach is primarily an approach to the anterior column and inner aspect of the innominate bone. The entire internal iliac fossa as well as the pelvic brim are exposed. The quadrilateral surface is also visualized through this approach. Though it is primarily an approach to the anterior column a useful though less effective approach to the posterior column is available through manipulation of the quadrilateral surface (Figure 7). The final reduction of the articular surface cannot be directly visualized, however it is assumed to be correct after the restoration of the internal contour of the innominate bone.

The ilioinguinal approach is initiated for anterior wall, anterior column, associated anterior and posterior

hemitransverse, most both-column and certain transverse fractures (Figure 8). It is indicated for old anterior wall and anterior column fractures.

Prior to procedure a Foley catheter is inserted into the bladder. The patient is placed in a supine position on the PROfx® Surgery Table with the lower extremities in traction through the traction boots attached to traction units on the table. The lateral traction device is made available for the possibility of pulling lateral traction through a femoral head corkscrew placed into the greater trochanter during the operation (Figure 9).

The Incision starts at the mid-line two finger breadths proximal to the symphysis pubis.

It proceeds laterally to the anterior-superior spine of the ilium and then follows the iliac crest two-thirds of the way posteriorly along the crest. The incision should extend beyond the lateral most convexity of the ilium (Figure 10). The periosteum is sharply incised along the iliac crest releasing the attachment of the abdominal muscles and iliacus from the crest. A periosteal elevator is used to expose the internal iliac fossa as far posteriorly and medially as the sacroiliac joint and pelvic brim. The first abdominal layer encountered is the aponeurosis of the external oblique and the external sheath of the rectus abdominis in the most medial portion of the incision. This layer is incised in line with the skin incision and then reflected distally to unroof the inguinal canal. The spermatic cord or round ligament with the accompanying ilioinguinal nerve is located in the inguinal canal and a Penrose drain placed around these structures for retraction (Figure 11). An incision is then made long the entire length of the inguinal ligament. Approximately one millimeter of the length of the ligament is split away from the main portion of the ligament. Medially the transversalis fascia is thereby released from the inguinal ligament and laterally the common origin of the internal oblique and transverses abdominis are released from the inguinal ligament. Care must be taken in this incision as the external iliac vessels and lymphatics lie immediately below the medial portion of the inguinal ligament and the lateral cutaneous nerve is found immediately below the lateral portion of the ligament. It is also usually necessary to incise a portion of the conjoined tendon at its insertion to the pubis just medial to the transversalis fascia and additionally transect a portion of the rectus abdominis tendon at its insertion on the pubis. After this incision along the inguinal ligament is

completed, the surgeon has now exposed the retropubic space of Retzius in the medial portion of the incision. The external aspect of the femoral vessels and the surrounding lymphatics are exposed in the mid-portion of the incision and the psoas sheath has been entered in the lateral portion of the incision with visualization of the lateral cutaneous nerve of the thigh and the femoral nerve within the psoas sheath (Figure 12).

The iliopectineal fascia will be found to divide the femoral vessels and lymphatics from the iliopsoas muscle and femoral nerve (Figure 13). The vessels and lymphatics should be dissected away from the muscle and nerve away from the fascia laterally. The iliopectineal fascia is then sharply incised to the pectineal eminence followed by detachment of the iliopectineal fascia from the pelvic brim proximally to the anterior sacroiliac joint (Figures 14, 15, 16). The iliopectineal fascia separates the false pelvis from the true pelvis. Detachment of the fascia from the pelvic brim allows access to the true pelvis and thereby the quadrilateral surface and posterior column. Another Penrose drain is placed around the iliopsoas and femoral nerve which also includes the lateral cutaneous nerve of the thigh. A third Penrose drain is then placed around the femoral vessels and lymphatics. The vessels should be left within the fatty areolar tissue that surrounds them because this fatty areolar tissue contains the lymphatics which should not be disrupted.

In Approximately 10 percent of the cases there is either an anastomosis between the obturator vessels and the external iliac vessels or an abnormal origin of the obturator artery from the external iliac vessels. The surgeon should inspect posterior to the vessels to check for this possibility.

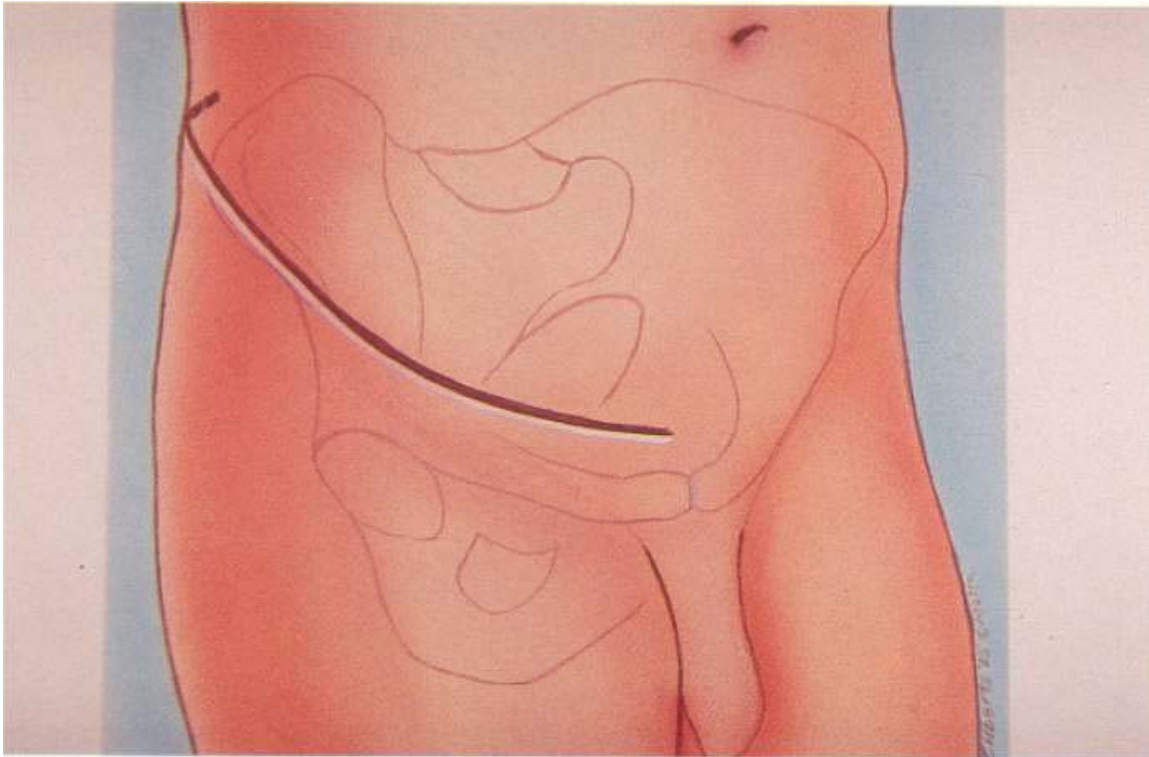


Figure 10. Skin incision for the ilioinguinal approach.

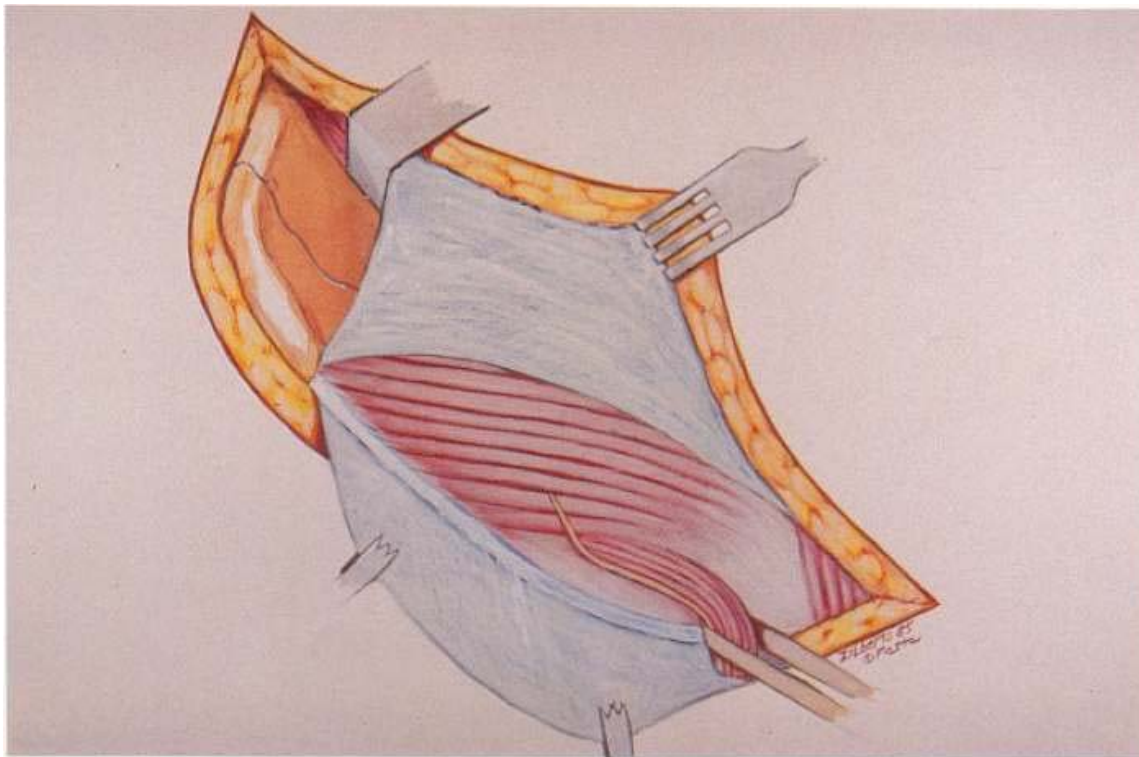


Figure 11. Unroofing of the inguinal canal.

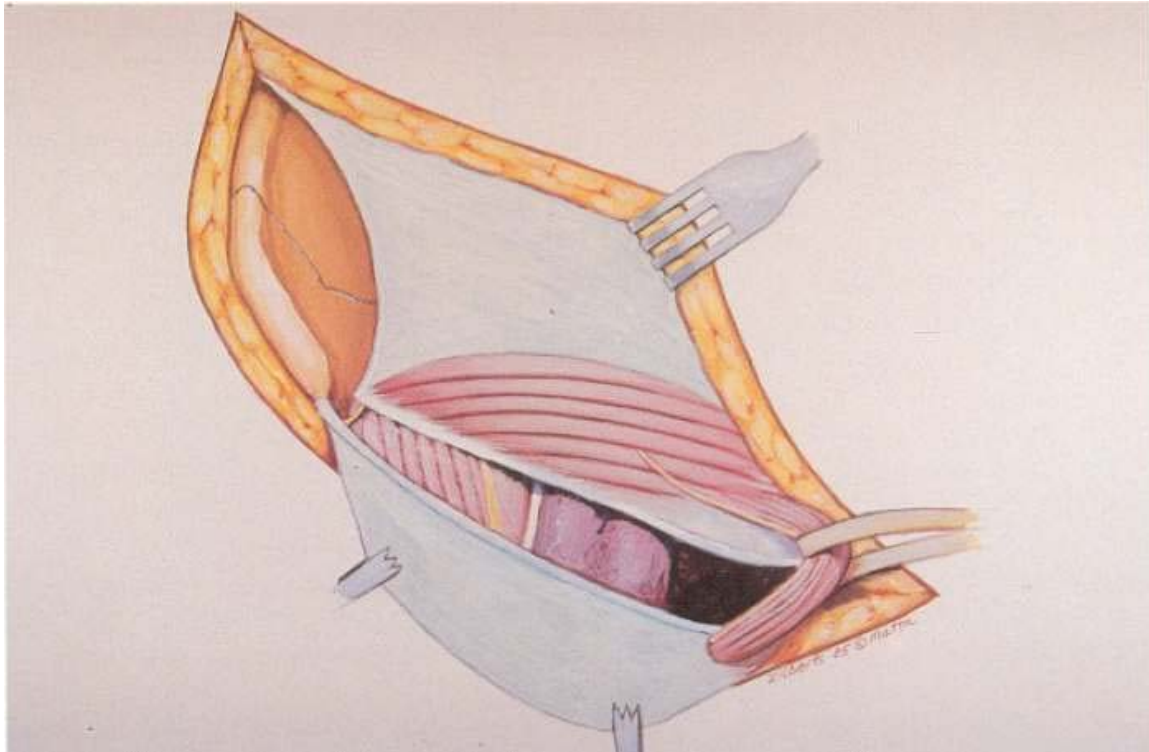


Figure 12. Detachment of the abdominal muscles and transversalis Fascia from the inguinal ligament.

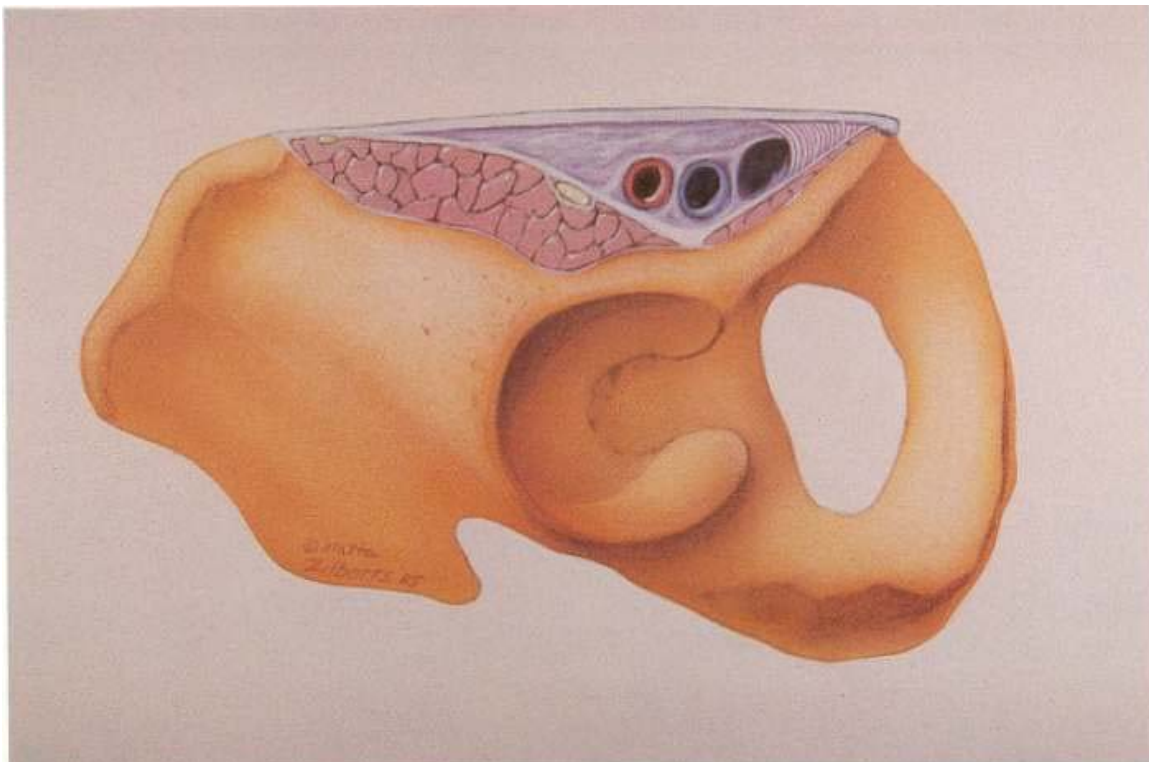


Figure 13. Oblique section of the lacuna musculorum and lacuna vasculorum at the level of the inguinal ligament.

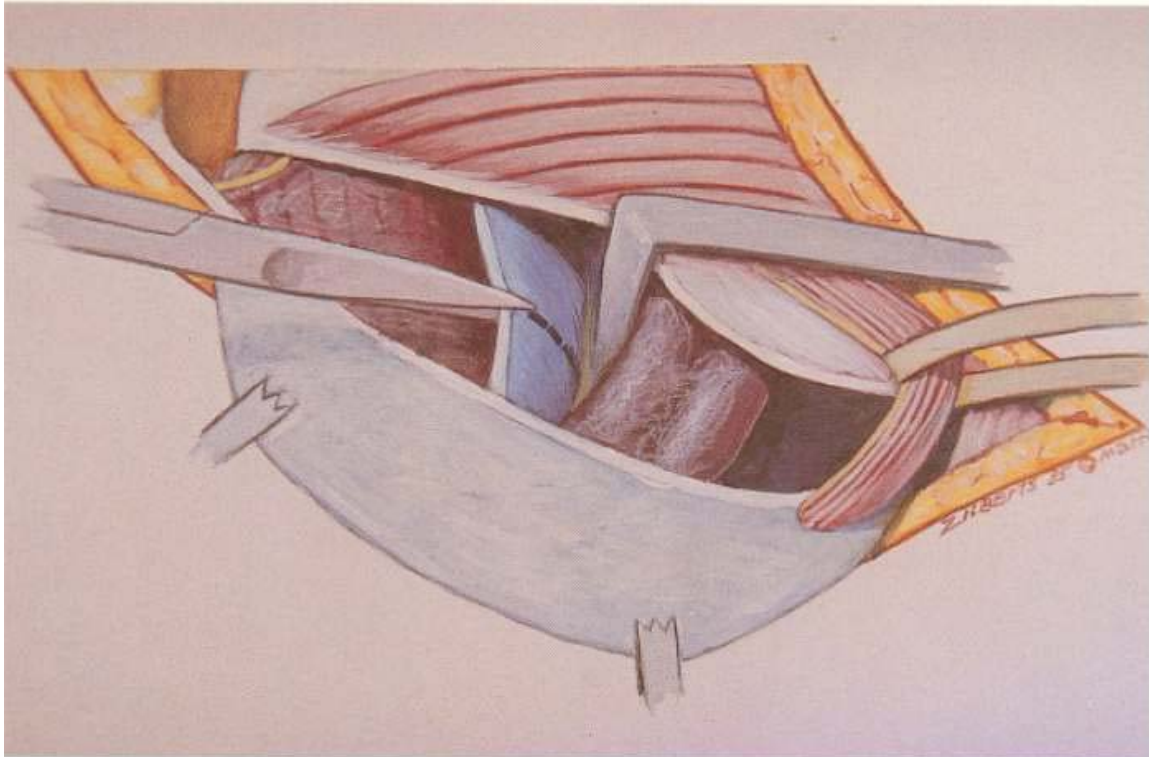


Figure 14. Division of the iliopectineal fascia.

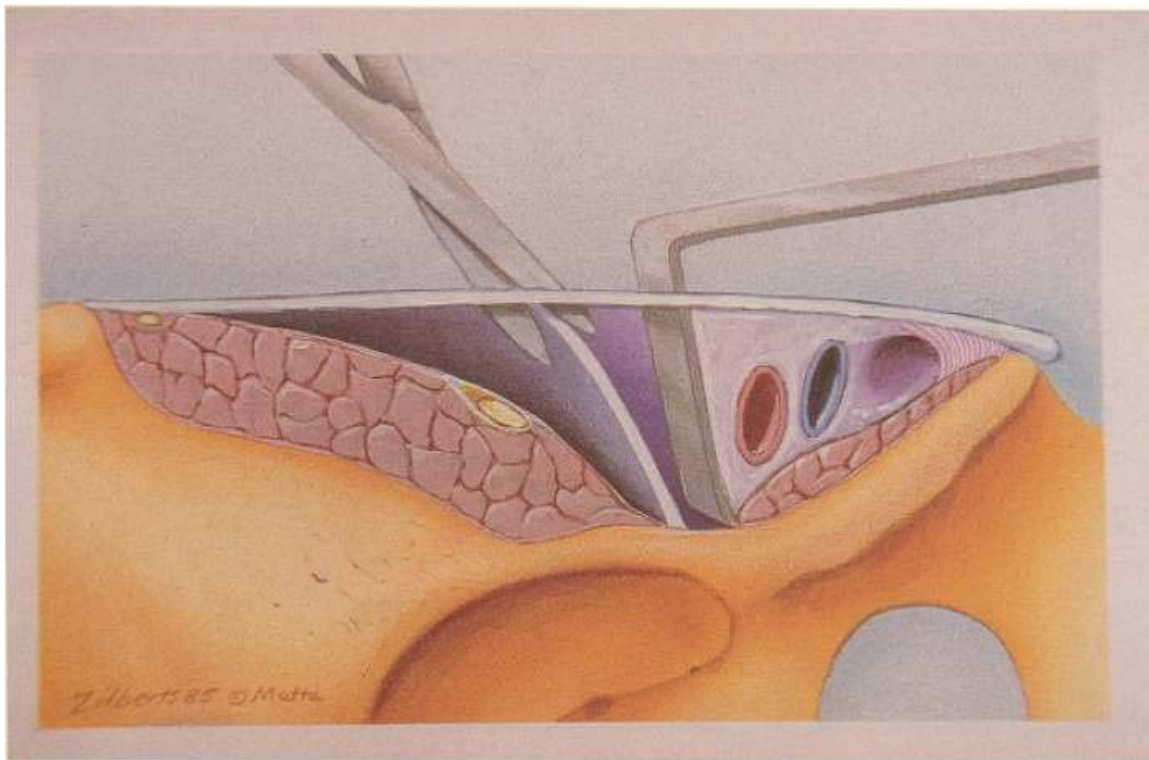


Figure 15. Oblique section dividing the fascia.

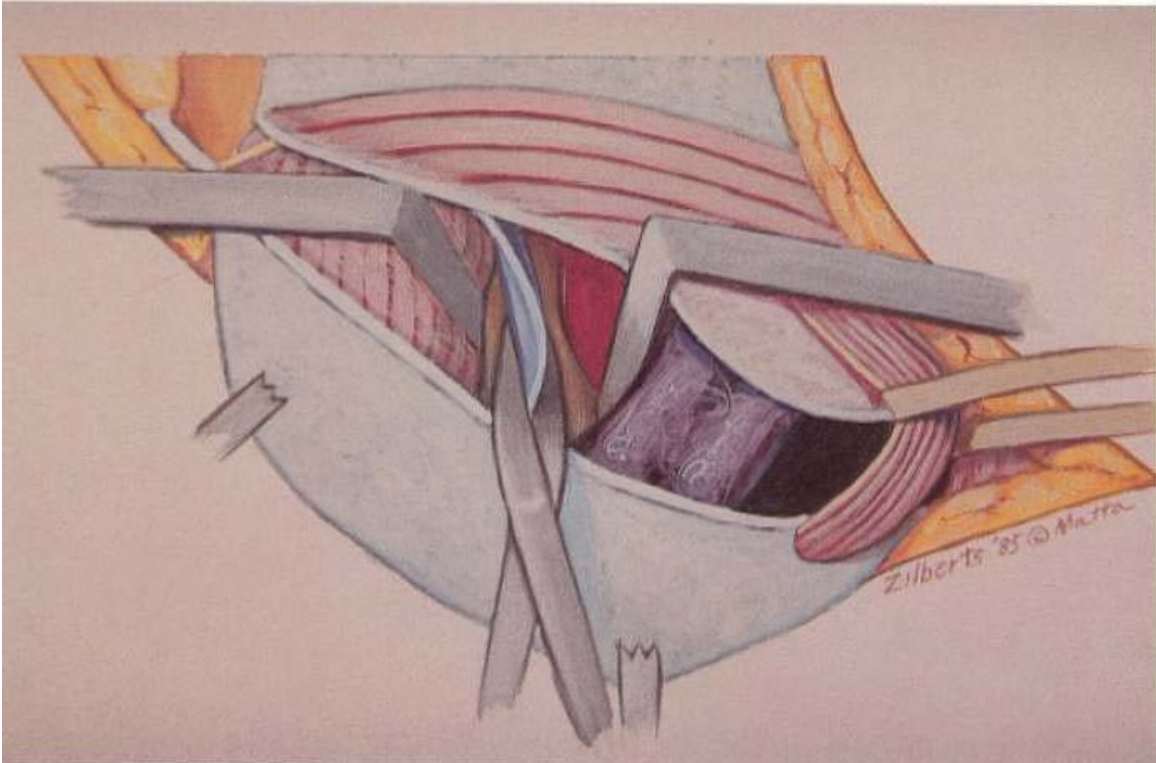


Figure 16. Proximal division of the fascia from the pelvic brim.

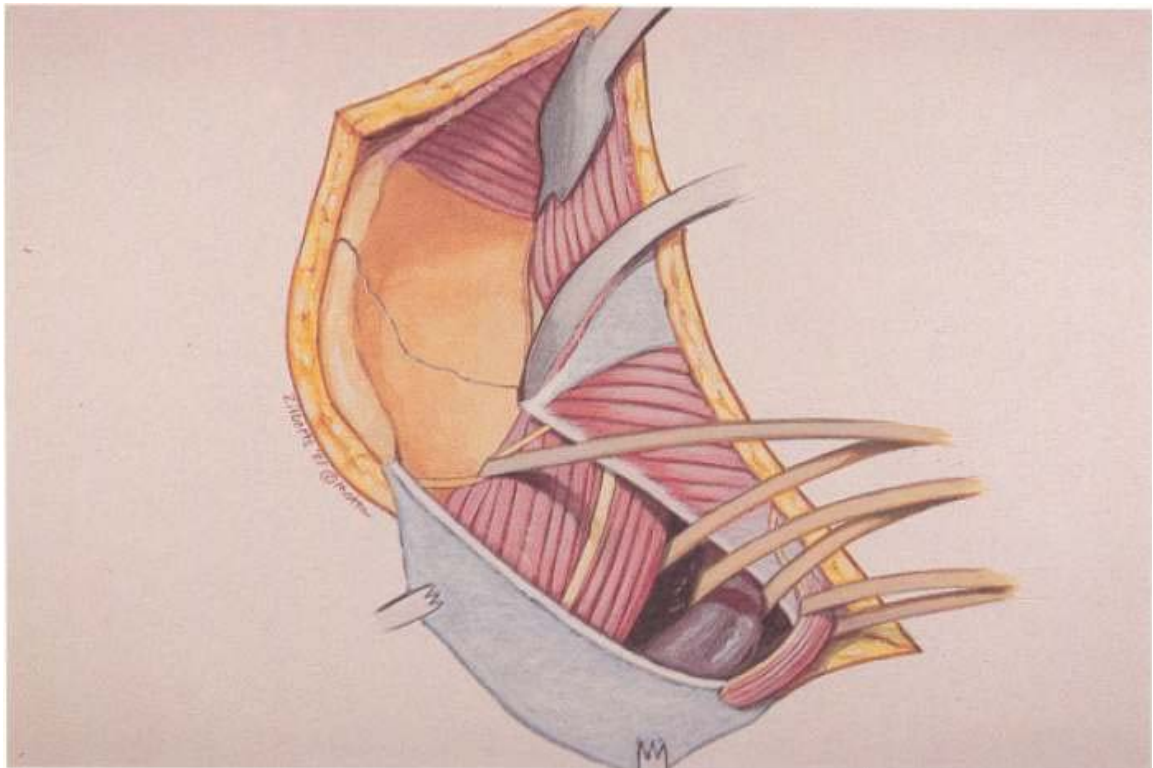


Figure 17. The first window of the ilioinguinal approach.

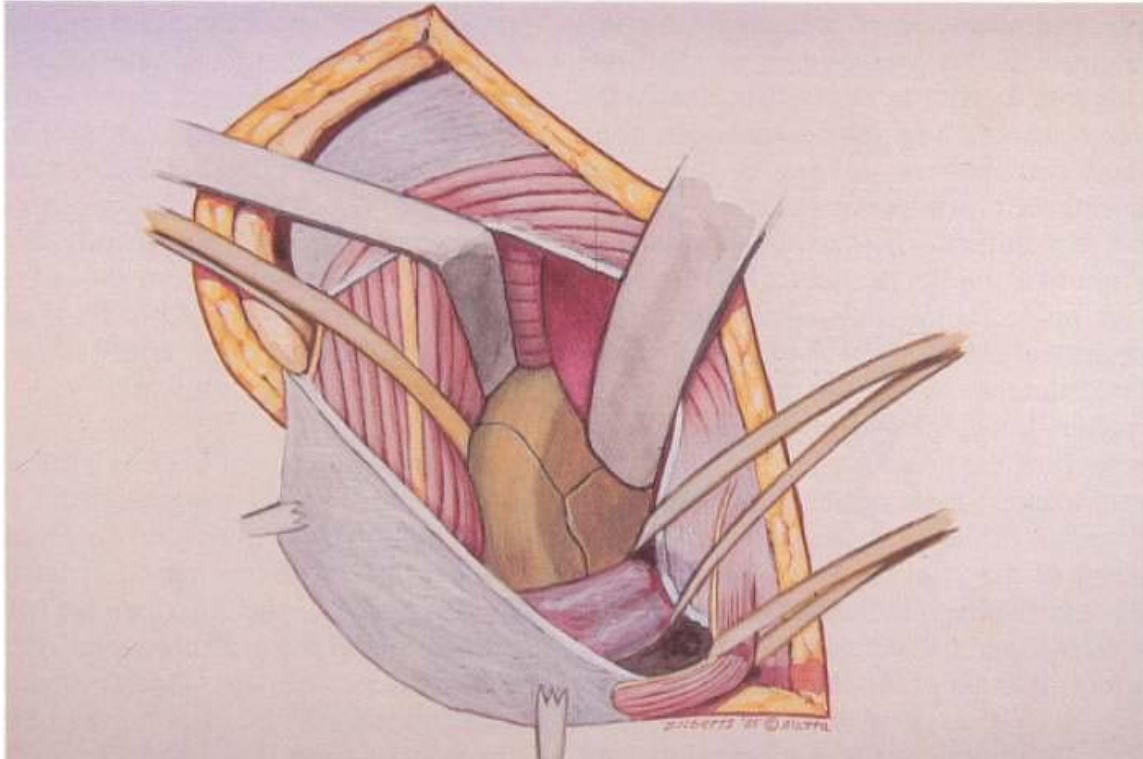


Figure 18. The second window of the ilioinguinal approach.

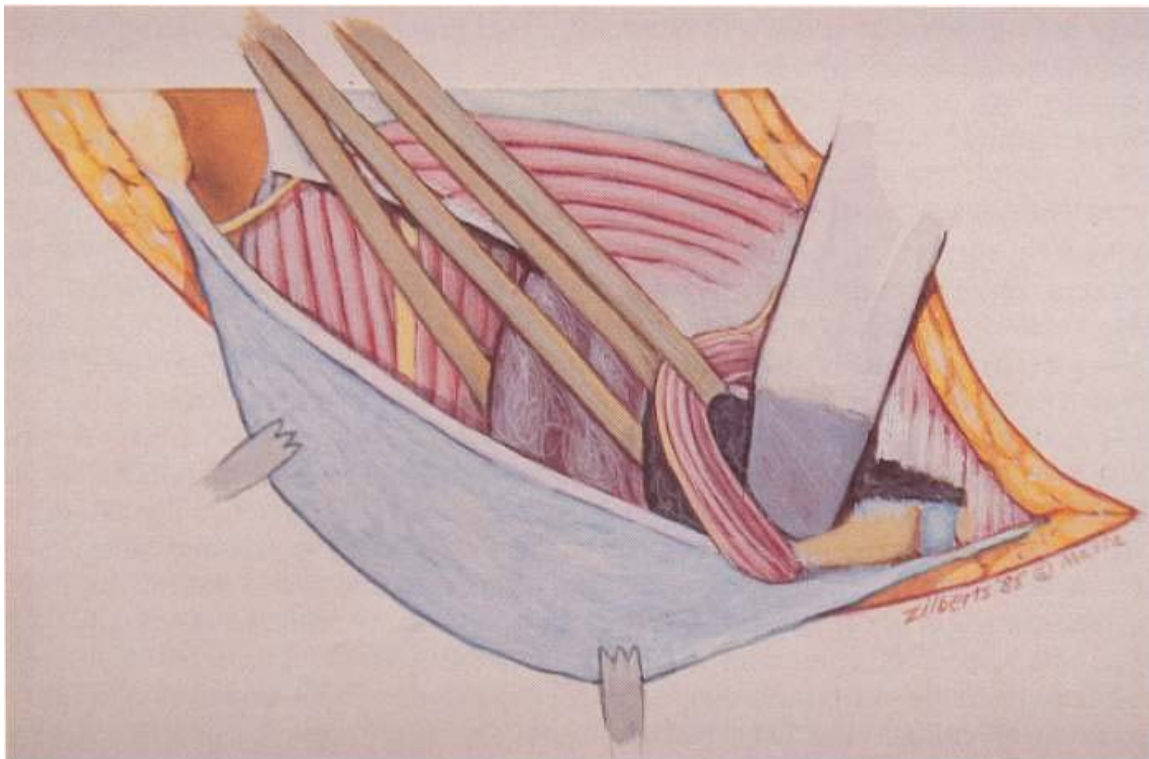


Figure 19. Access to the retropubic space and symphysis.

If this anastomosis or abnormal origin to the obturator artery is present the vessels should be clamped, transected and ligated to prevent tearing of the vessel during the procedure and bleeding that can be very difficult to control. A periosteal elevator is used to further expose the superior pubic ramus and pelvic brim. The periosteal elevator can also be used on the quadrilateral surface for visualization of fracture lines. In doing this, take care in approaching the greater sciatic notch as it is easy to injure the superior gluteal vessels or branches of the internal iliac vein. The interior of the joint can often be visualized through the fracture lines while the fracture is displaced, however cannot be inspected after reduction of the fracture.

The exposure is now complete and the operation will be performed through the various windows surrounded by the structures crossing the inguinal ligament. The first window gives access to the internal iliac fossa, the anterior sacroiliac joint and the pelvic brim (Figure 17). Retraction can be performed with lever retractors placed on the anterior sacroiliac joint and the pelvic brim.

The second window, which is obtained by retracting the iliopsoas and femoral nerve laterally and the external iliac vessels medially, gives access to the pelvic brim from the anterior sacroiliac joint to the pectineal eminence (Figure 18). It also gives access to the quadrilateral surface for reduction of posterior column fractures. The iliopsoas can be retracted fairly vigorously laterally without danger of injury to the femoral nerve. Take care in the medial retraction of the external iliac vessels; this is usually done with a ribbon retractor with its tip placed against the quadrilateral surface.

Following retraction of the vessels, check the pulse repeatedly to make sure that too great a force has not been applied. Medial to the vessels, one has access to the superior pubic ramus and the symphysis pubis, if necessary (Figure 19). The spermatic cord may be retracted medially or laterally as required. The obturator nerve is visualized through either the second or third window of the ilioinguinal approach as it passes under the superior pubic ramus.

It is often useful to detach the sartorius and inguinal ligament from the anterior-superior spine and to elevate the tensor fascia lata muscle from the outer portion of the anterior iliac wing. This access to the external aspect of the bone is often useful for placing reduction clamps across the anterior border of the innominate bone.

At the completion of the procedure Hemovac drains are placed in the retropubic space of Retzius along the quadrilateral surface as well as the internal iliac fossa. If the external aspect of the bone has been exposed this should also be drained. Full muscle relaxation should be employed throughout the closure of the incision. The abdominal muscles tend to retract in a proximal and posterior direction and must be restored to their anatomic position along the iliac crest in order to obtain a sound closure of the floor and roof of the inguinal canal. If the origin of the sartorius has been detached it is reattached with a suture placed through a drill hole on the anterior-superior spine. The floor of the inguinal canal is repaired along the inguinal ligament and the roof of the inguinal canal repaired by closure of the aponeurosis of the external oblique. The iliopectineal fascia is not repaired.

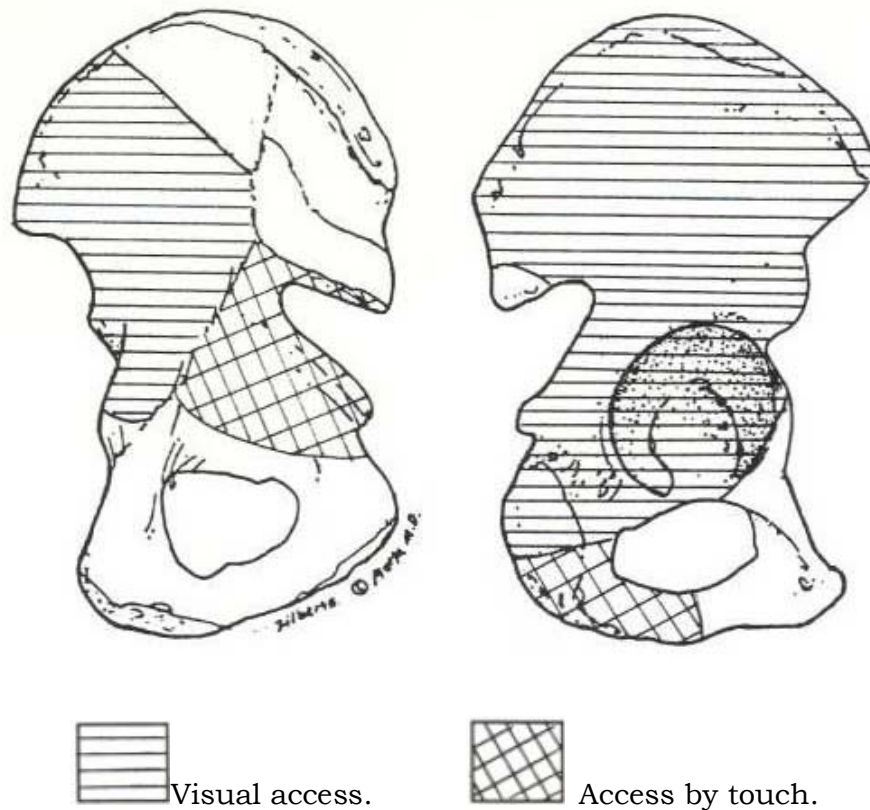


Figure 20. Access to the bone with the extended iliofemoral approach.

EXTENDED ILIOFEMORAL APPROACH

The extended iliofemoral approach was developed by Emile Letournel as a surgical approach to provide maximum simultaneous access to both columns of the acetabulum. It is primarily an approach to the external aspect of the innominate bone giving access to the entire lateral aspect of the iliac wing, the entire retroacetabular surface and the interior of the hip joint following a capsulotomy along the acetabular rim. A limited exposure to the internal aspect of the bone is possible by exposing the internal iliac fossa. The anterior column may be followed distally to the pectineal eminence (Figure 20). Access beyond the pectineal eminence is limited by the tendon of the iliopsoas.

This approach may be thought of as the lateral approach to the acetabulum and innominate bone. This exposure follows a logical neurovascular interval reflecting muscles enervated by the femoral nerve medially.

The extended iliofemoral approach is indicated for certain both column, certain T-shaped and certain associated transverse plus posterior wall fractures (Figure 21). It is indicated for old transverse, transverse plus posterior wall, T-shaped, associated anterior plus posterior hemitransverse, and both column fractures.

Prior to the operation a Foley catheter is placed in the bladder. A transcondylar Steinmann pin is placed through the distal femur for intraoperative traction.

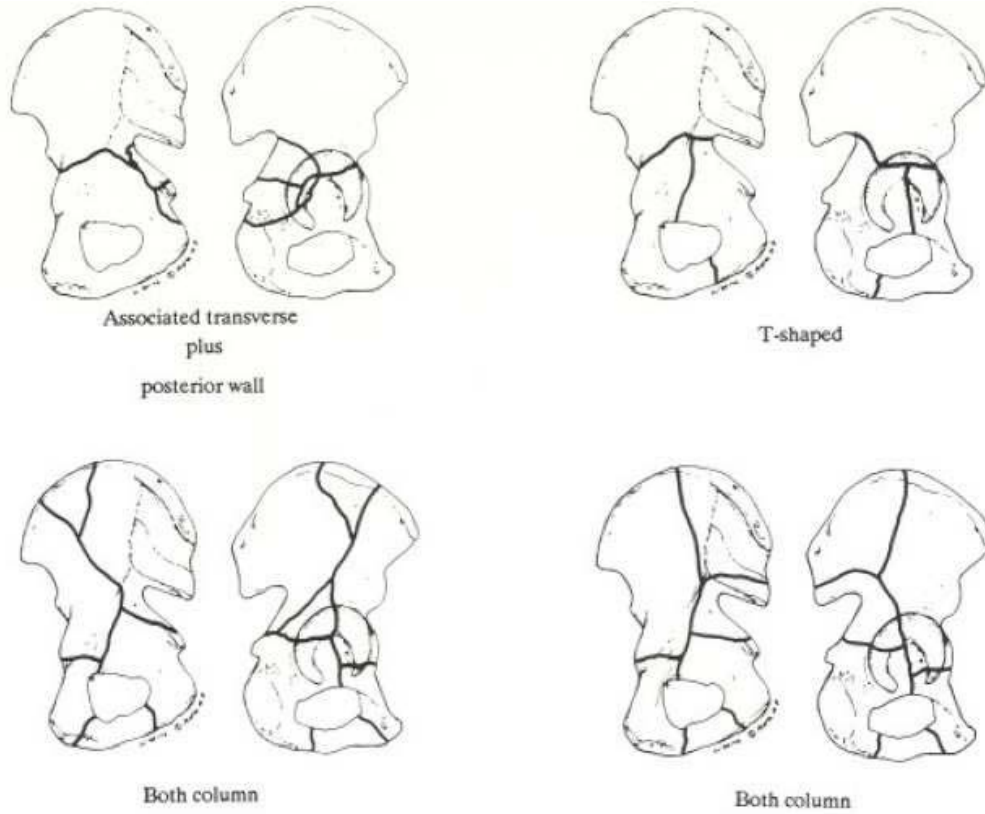


Figure 21. Fractures operated through the extended iliofemoral approach.

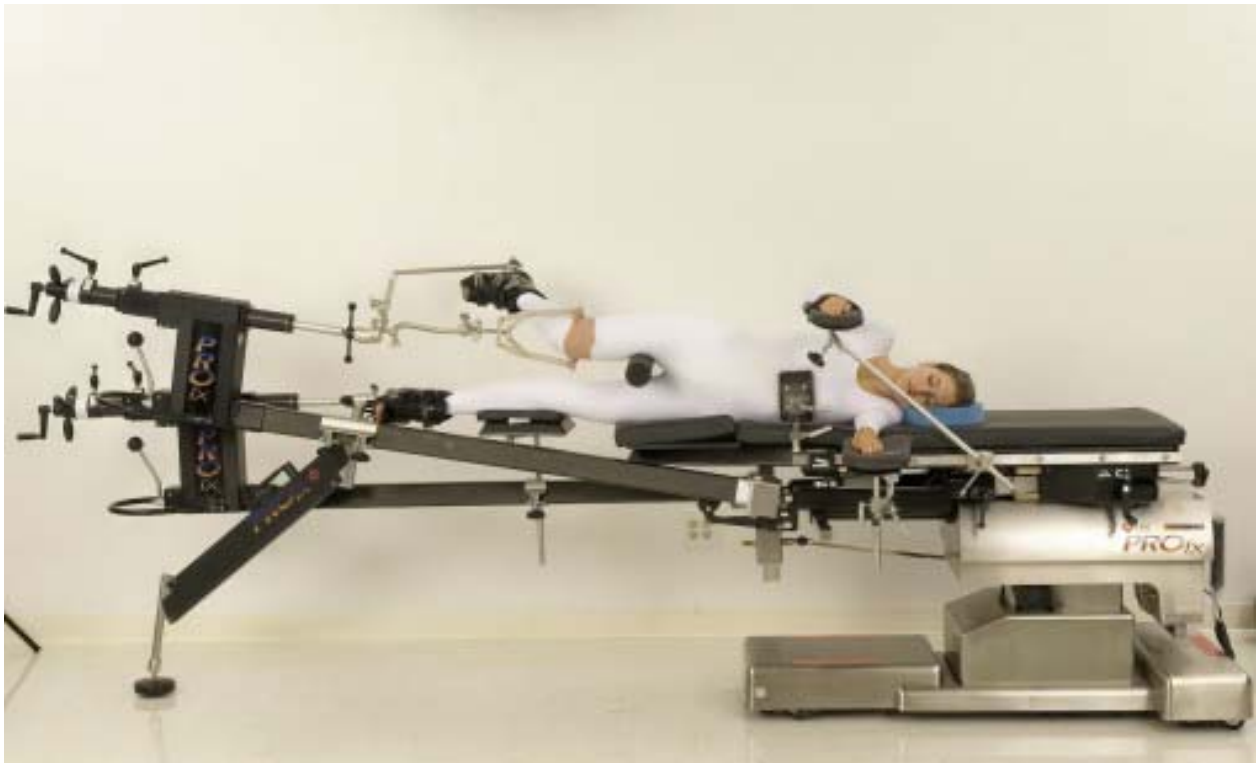

Figure 22. Positioning of the patient on the PROfx® Pelvic Reconstruction Orthopedic Fracture Table for operations through the extended iliofemoral approach.

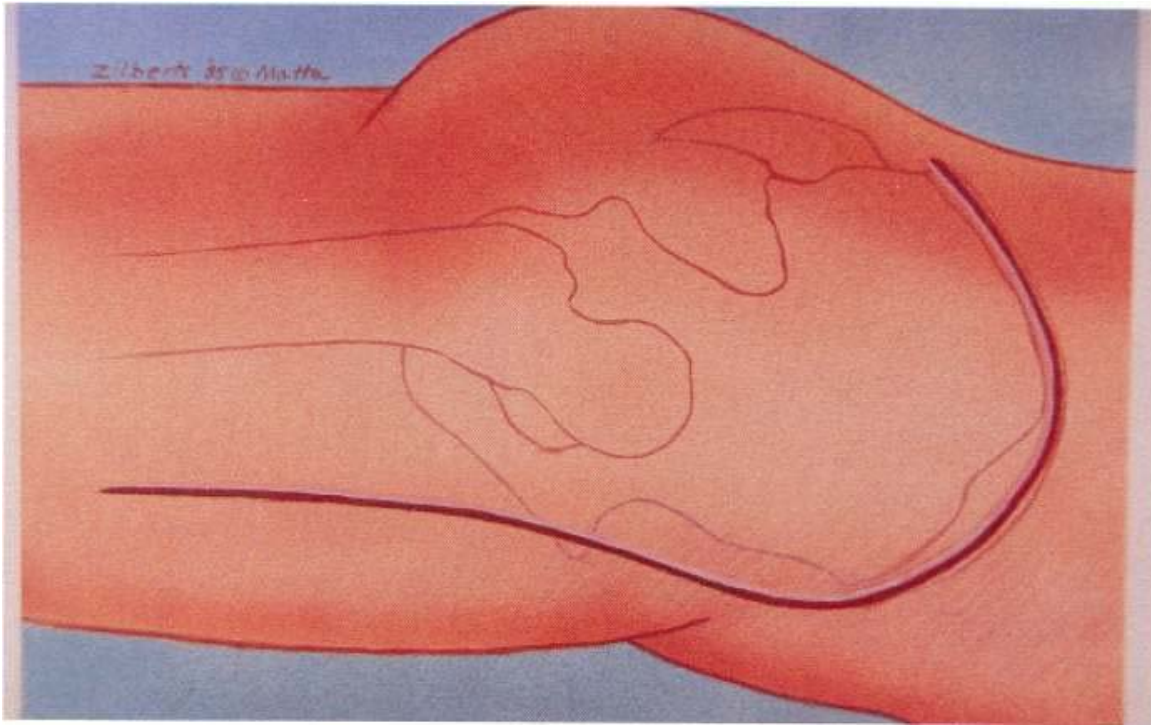


Figure 23. Skin incision for the extended iliofemoral approach.

The patient is placed in the lateral position on the PROfx® Surgery Table. The knee is kept flexed at least 60 degrees to relax the sciatic nerve. The lateral perineal post may be raised and lowered intraoperatively to provide lateral traction to the hip (Figure 22).

The incision starts at the posterior superior spine and proceeds around the entire length of the iliac crest to the anterior-superior spine and then anterolaterally down the thigh (Figure 23). The periosteum is sharply incised over the iliac crest. The fascia lata is released from the crest. A periosteal elevator is used to dissect the gluteal muscles and tensor fascia lata from the external aspect of the iliac wing. The Most posterior portion of the gluteus maximus origin is usually left attached to the iliac wing. The fascia lata is incised over the anterolateral thigh exposing the tensor fascia lata muscle. The incision is usually continued

distally enough to expose the distal extent of the tensor fascia lata muscle. The tensor fascia lata is retracted posteriorly exposing the fascia layer which separates it from the rectus femoris. This fascia layer is incised longitudinally. A second fascia layer which separates the rectus femoris from the vastus lateralis is also incised longitudinally. Immediately beneath this fascia layer are found the lateral femoral circumflex vessels which are clamped, transected and ligated (Figure 24). Strong aponeurotic fibers that cross the anterior portion of the greater trochanter are transected.

The elevation of the gluteal muscles from the iliac wing is continued in a posterior and distal direction until the greater sciatic notch is reached. The greater sciatic notch must be approached with care to avoid injury to the superior gluteal nerve or vessels.

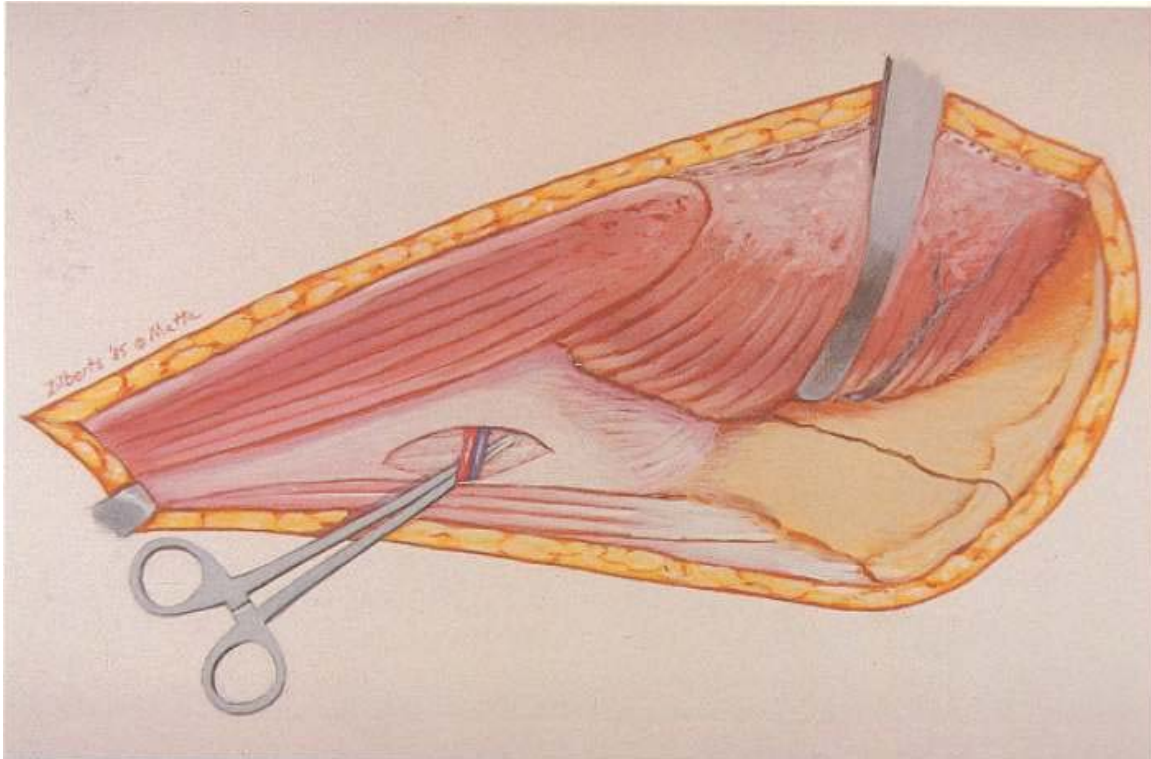


Figure 24. Exposure of the lateral femoral circumflex vessels.

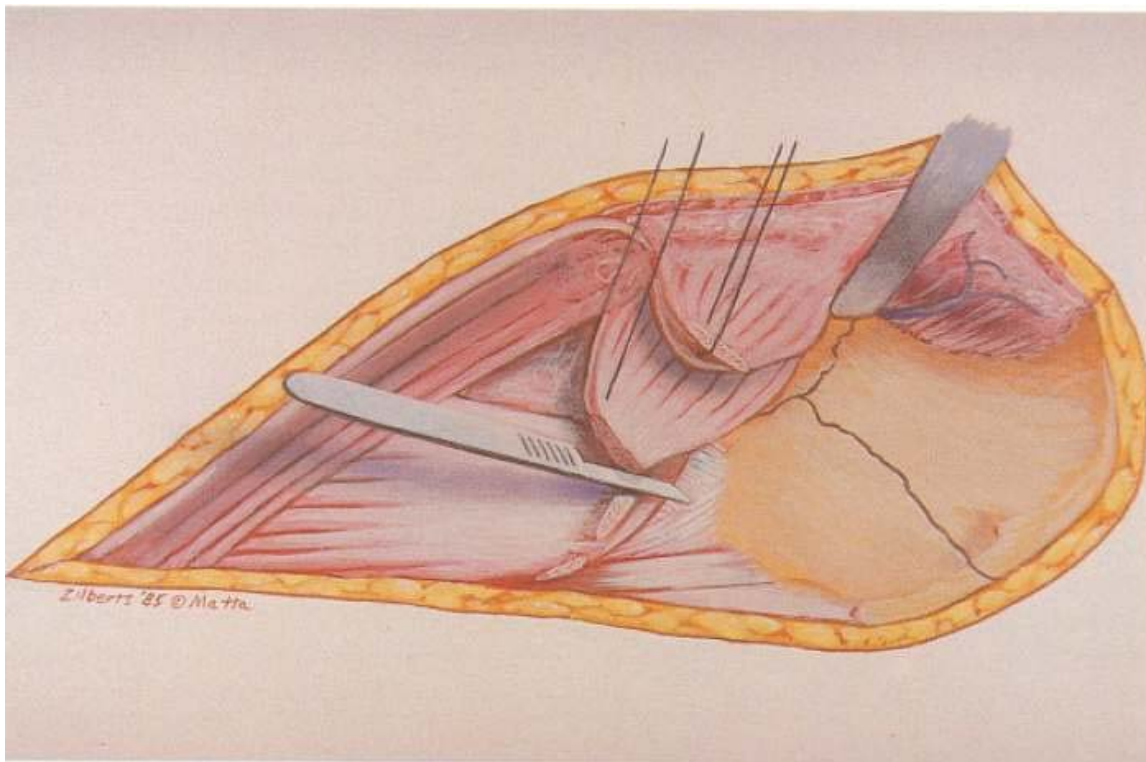


Figure 25. Transection of the gluteus minimus and gluteus medius tendons.

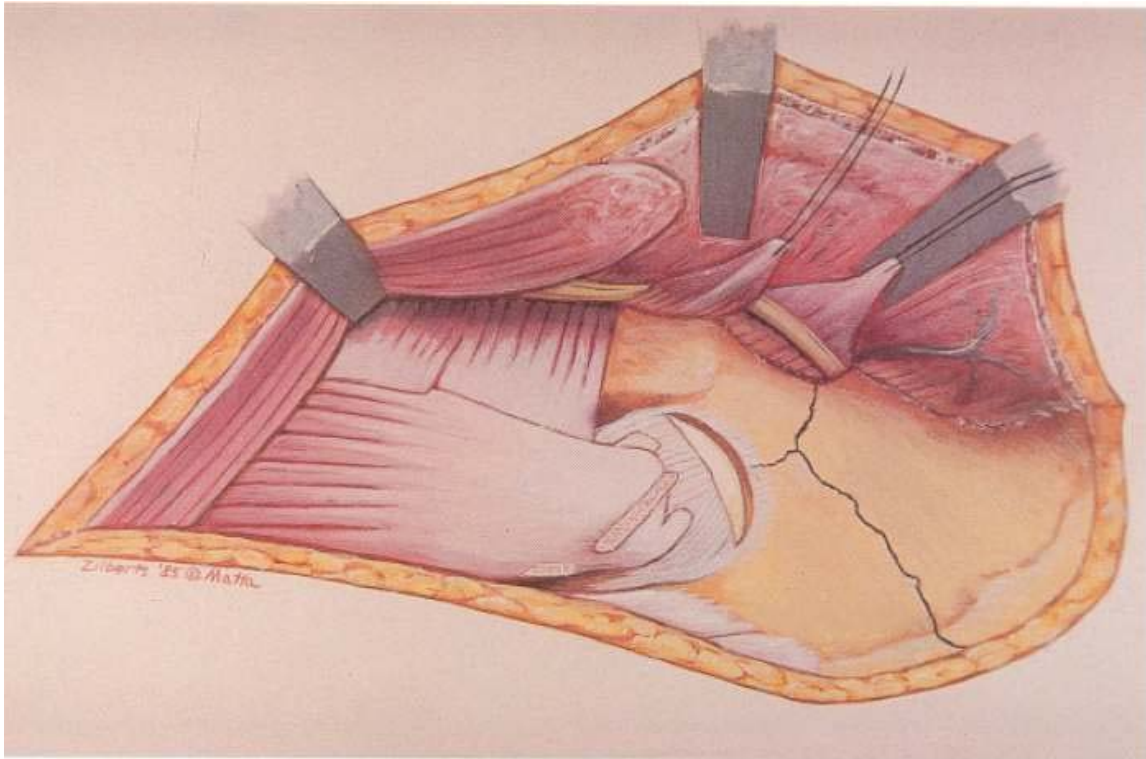


Figure 26. Completed exposure of the external aspect of the bone.

The tendon of the gluteus minimus is identified at its anterior insertion on the trochanter. It is tagged with a suture and then transected in its mid-substance. The gluteus minimus also attaches to the superior hip capsule and this insertion is also detached from the hip capsule. The gluteus medius tendon is identified as a broad band on the external aspect of the greater trochanter about 15 millimeters in length. The tendon is transected in its mid-substance and tagged with multiple sutures (Figure 25). The surgeon will find the thickest and strongest portion of the tendon to insert posterior and superior on the greater trochanter. The piriformis tendon is identified at its insertion on the superior portion of the trochanter. It is transected and the muscle reflected posteriorly further exposing the greater sciatic notch. The tendon of the Obturator internus along with the two gemellae is tagged with suture and

transected at its posterior trochanteric insertion. As it is reflected posteriorly, the bursa of the obturator internus and the lesser sciatic notch are identified as with the Kocher-Langenbeck approach. Retractors can now be placed in the greater and lesser sciatic notch for retraction (Figure 26).

Excision of the reflected head of the rectus femoris muscle gives better access to the superior hip capsule. A capsulotomy may be performed at the rim of the acetabulum and traction applied with the PROfx® Surgery Table will distract the femoral head from the acetabulum and allow visualization of the interior of the joint. The internal iliac fossa may be exposed by detachment of the abdominal muscles from the iliac crest as well as detachment of the sartorius and inguinal ligament from the anterior-superior spine.

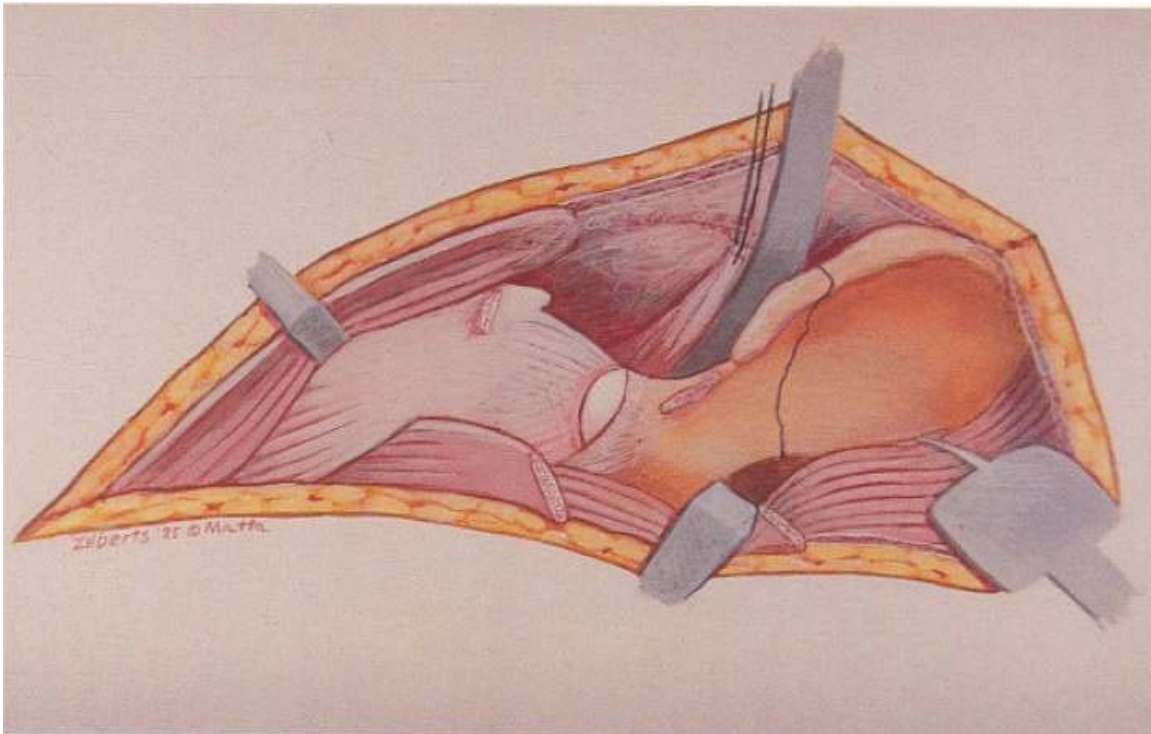


Figure 27. Exposure of the internal iliac fossa.

The dissection may be carried out posteriorly and medially to the anterior sacroiliac joint and pelvic brim. Transection of the direct head of the rectus femoris at its bony origin will complete the maximum access to the anterior column (Figure 27).

In the case of a T-shaped fracture in which no fracture lines transverse the iliac wing, both sides of the iliac wing may be exposed without fear of devascularizing the bone. In the case of a both-column fracture, however, the anterior column fracture usually traverses the anterior portion of the wing to iliac crest. In this case complete exposure of both sides of the iliac wing may easily devascularize a large segment of the anterior column. In order to prevent tins soft tissue pedicles must remain attached to the anterior column for vascularity. At a minimum the direct head of the rectus femoris and anterior hip capsule should be left attached to the anterior column. Throughout the operation the large

gluteal muscle flap should be protected against dessication by keeping the exposed muscle covered with a wet sponge.

At the completion of the operation suction drains are placed along the course of the rectus femoris and vastus lateralis. These drains should lead to the external iliac fossa and greater sciatic notch. If the internal aspect of the bone has been exposed this should be drained as well. If the rectus femoris and sartorius origins have been released these muscles should be reattached to the bone by suture placed through drill holes. The tendons of the obturator internus and piriformis are reattached. The tendons of the gluteus medius and gluteus minimus are reattached with multiple sutures to the tendon stumps remaining on the greater trochanter. The fascia lata is reapproximated to the abdominal fascia along the iliac crest and the fascia lata is closed anterolaterally over the thigh.

Reattachment of the fascia lata to the abdominal fascia along the iliac crest can be greatly facilitated by abduction of the hip. Reattachment of the sartorius and rectus femoris origins is facilitated by flexing the hip and extending the knee.

POSTOPERATIVE CARE

The postoperative surgical care is essentially the same for all three of the surgical approaches to the acetabulum. Prophylactic antibiotic which is started preoperatively is continued for 72 hours postoperatively. The suction drainage is continued typically for 48 hours postoperatively though may be extended to 72 hours with continued drainage.

Passive mobilization of the hip, either with physical therapist or with continuous passive motion machine, may be started within the first few days after surgery. Gait training can be started when the patient is comfortable enough, which is usually between five and ten days following the operation. The patient's weight bearing is limited to 15 kilograms for the first eight weeks following the operation and then weight bearing is progressed as tolerated.

If the fracture is accurately reduced and ectopic bone does not develop, the range of motion usually returns to 90 percent of normal without problems. Physical therapy is directed primarily toward muscle strengthening of the abductor musculature.

Following the Kocher-Langenbeck and extended iliofemoral approach in domethacin is usually administered 25 milligrams, three times daily for two months after the operation. No prophylaxis against ectopic bone is necessary with the ilioinguinal

approach. Radiation can be considered if the risk of ectopic bone is considered to be unusually high.

SURGICAL APPROACHES FOR PELVIS FRACTURE

Unstable fractures of the pelvis invariably involve combined lesions to both the anterior and posterior pelvic ring, and may require staged approaches. In the great majority of cases the posterior lesion is approached first, followed by repositioning of the patient for operation of the anterior lesion. In many cases reduction and internal fixation of the posterior lesion will suffice. The approaches used for these staged procedures are described in this section. In a minority of cases it is possible to approach both lesions simultaneously through the ilioinguinal approach.

THE APPROACH TO THE SYMPHYSIS PUBIS

For the approach to the symphysis pubis the patient is placed supine position on the PROfx® Surgery Table. A Foley catheter is inserted into the bladder prior to the operation. The skin incision may be made either as a transverse incision two centimeters proximal to the symphysis pubis or as a vertical mid-line incision. The transverse incision is more cosmetic (Figure 28). The vertical incision may be extended for intra-abdominal access in the case of the multiple injury patient. Regardless of the direction of the skin incision, the deep dissection through the muscles is always the same. The alba is split longitudinally separating the two heads of the rectus abdominis.

In the case of an acute symphysis diastasis, one of the heads of the rectus abdominis is commonly torn from its bony attachment. As the linea alba is split distally, the paramedialis muscle is often encountered and this is also split longitudinally at its mid-portion (Figure 29). Directly beneath the abdominal wall one finds the peritoneal fat proximally and the bladder distally. In the acute injury, the bladder will fall away from the posterior surface of the symphysis as one enters the retropubic space of Retzius; however there may be adherence of the bladder to the bone from an old injury in which case it should be freed carefully with a periosteal elevator from the posterior aspect of the symphysis.

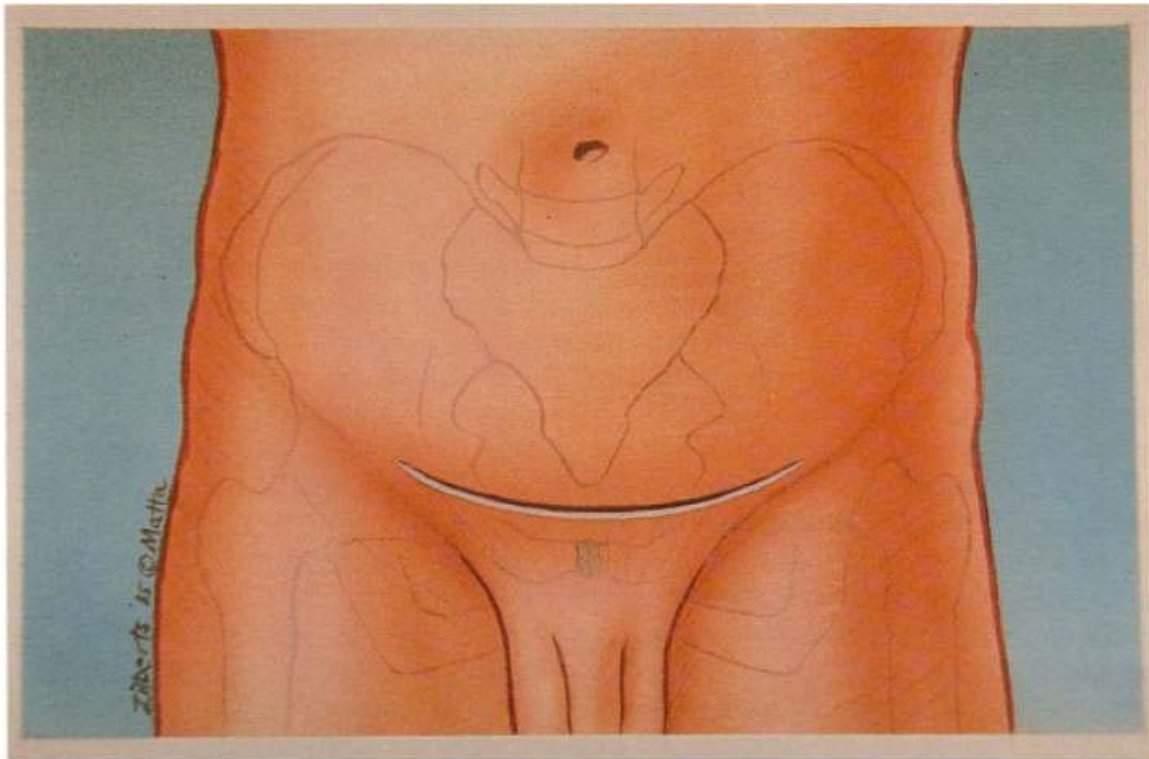


Figure 28. Skin incision for the approach to the symphysis pubis.

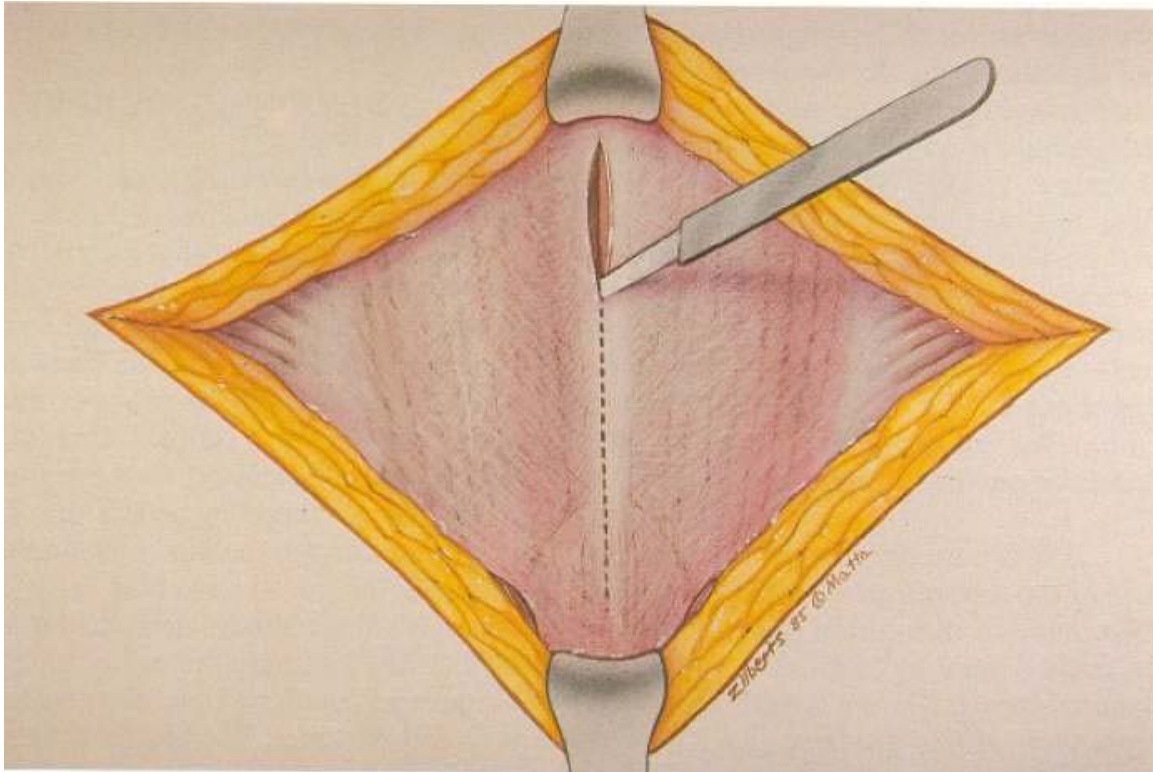


Figure 29. Incision along the linea alba.

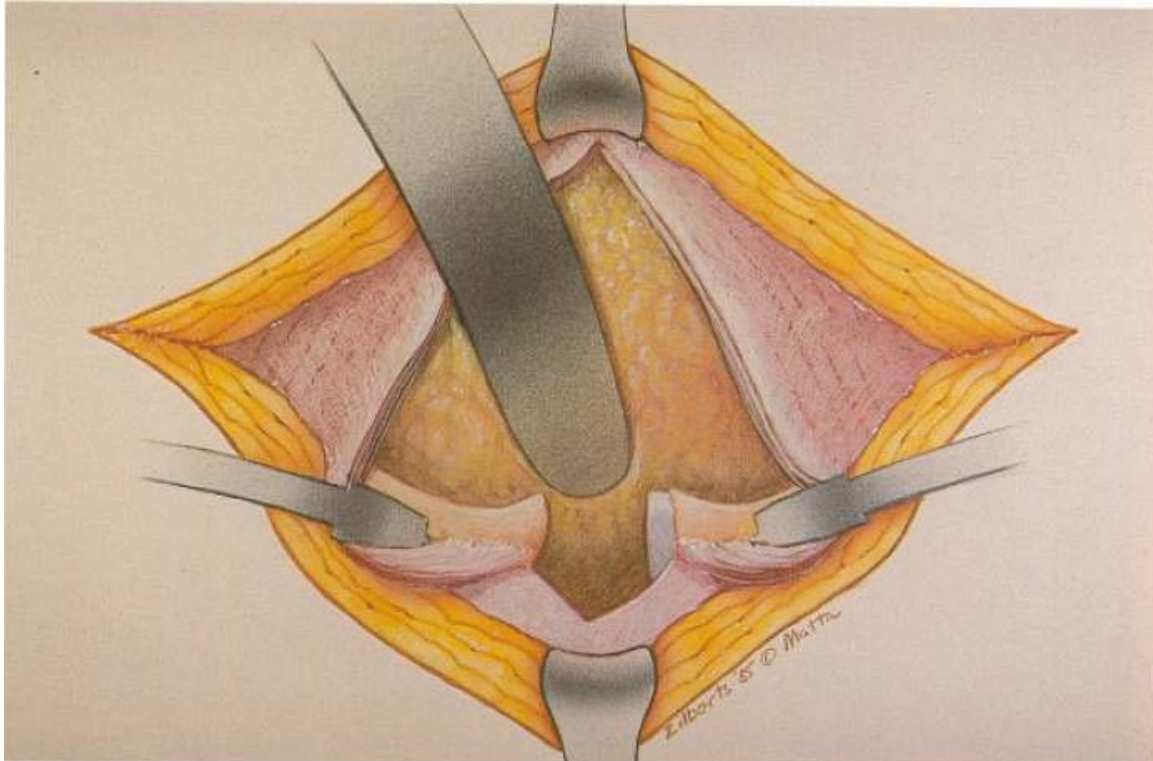


Figure 30. Retraction of the two heads of the rectus abdominus.

The two heads of the rectus abdominis are left attached to the anterior and outer aspect of the symphysis although the insertion is usually freed somewhat by sharp dissection from the superior aspect of the symphysis and superior pubis ramus. Hohmann retractors can be placed with their tips over the superior aspect of the mid-portion of the superior pubic ramus on each side in order to retract the two heads of the rectus abdominis laterally. Periosteal elevation along the superior part of the symphysis as well as the superior ramus completes the exposure necessary for reduction and plate application (Figure 30).

If it is necessary to approach a fracture of the superior pubic ramus as well as the symphysis dislocation this may usually be done simply by retraction of the abdominal muscles laterally with Hohmann retractors. If this does not give adequate access the tendon of the rectus abdominis may be transected near its insertion and the exposure continued laterally as with the ilioinguinal approach by opening the roof and floor of the inguinal canal. It is possible to approach the lateral-most aspect of the superior ramus while staying medial to the external iliac vessels. The surgeon should take care not to injure the obturator nerve or artery.

At the completion of the operation, a suction drain is placed in the retropubic space. Closure is normally simple with approximation of the two heads of the rectus abdominis along the linea alba and closure of the subcutaneous and skin. If one head of the rectus abdominis has been transected or the inguinal canal opened, repair these in the anatomic position.

THE APPROACH TO THE POSTERIOR PELVIC RING

A single surgical incision can be used to approach fractures of the sacrum, dislocations of the sacroiliac joint or fracture-dislocations of the sacroiliac joint. Prior to the operation a Foley catheter is inserted in the bladder. The patient is normally operated in the prone position on the PROfx® Surgery Table with the auxiliary Radiolucent Imaging Top attached (Figures 35 & 36). Use of the Radiolucent Imaging Top allows use of the image intensifier intraoperatively for targeting screws that can be placed through the iliac wing into the sacral ala or the S1 vertebral body. In order for the oblique views to be obtained with the image intensifier the pelvis must be positioned over the center of the Radiolucent Imaging Top that has no obstacles that would impede movement of image intensifier for at least 1.5 meters (Figure 31).

A vertical incision is made 2 centimeters lateral to the posterior-superior spine. The incision starts 5 centimeters proximal to the iliac crest and extends 5 centimeters distal to the superior border of the greater sciatic notch (Figure 32). The thin fascia overlying the gluteus maximus is identified. Subcutaneous tissue is reflected off the gluteal fascia posteriorly and medially to expose the gluteus maximus origin at the posterior iliac crest and from the sacrum. The periosteum is sharply incised along the posterior iliac crest to reflect the maximus muscle and a portion of the gluteus medius from the posterior and lateral aspect of the iliac wing. The maximus origin is also detached from the sacrum. As the gluteus maximus is detached from its origin over the sacrum it is lifted off the multifidus fascia which overlies the multifidus and erector spini muscles overlying the sacrum (Figure 33).

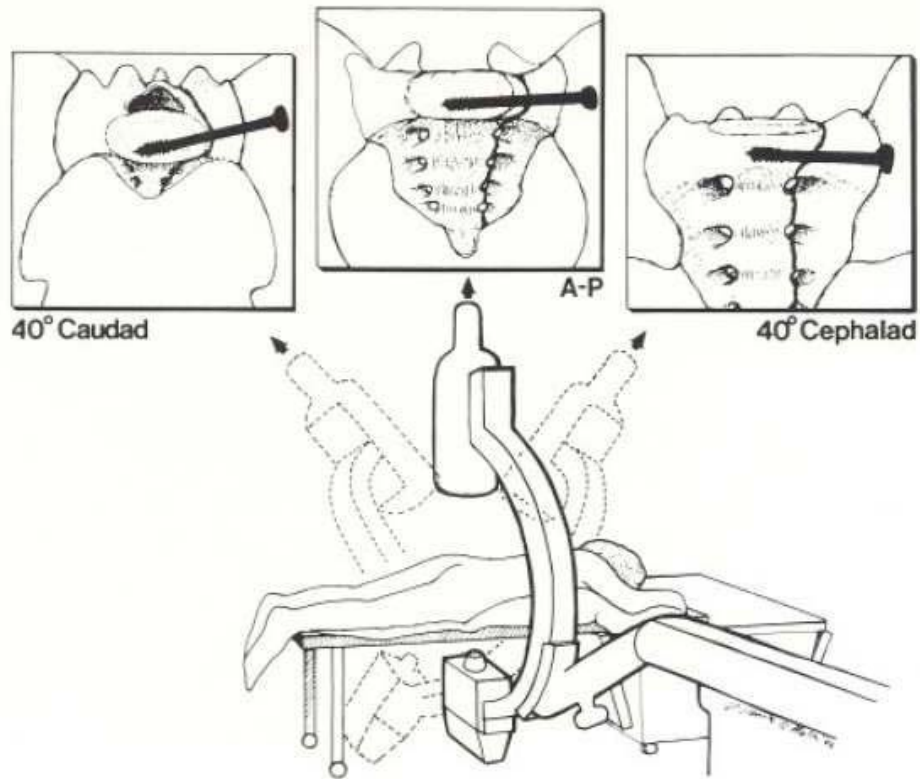


Figure 31. Prone positioning of the patient on the radiolucent table and use of the image intensifier for operations through the approach to the posterior pelvic ring.

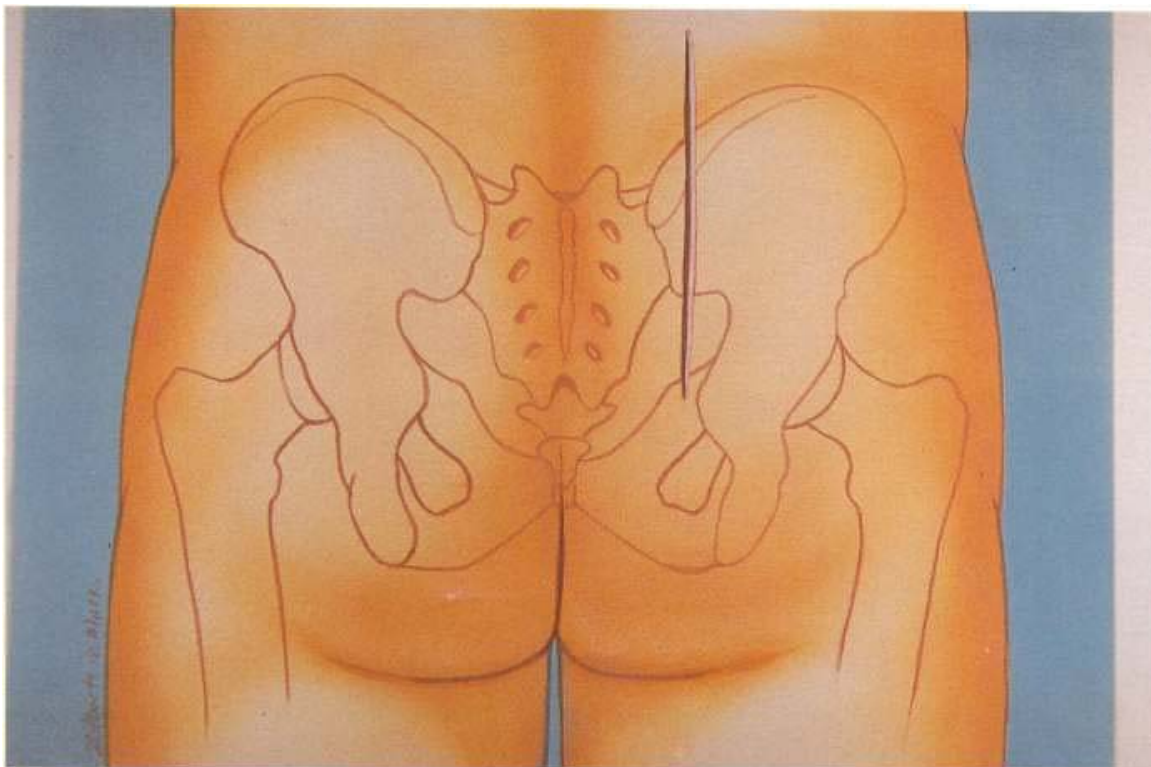


Figure 32. Skin incision for the approach to the posterior pelvic ring.

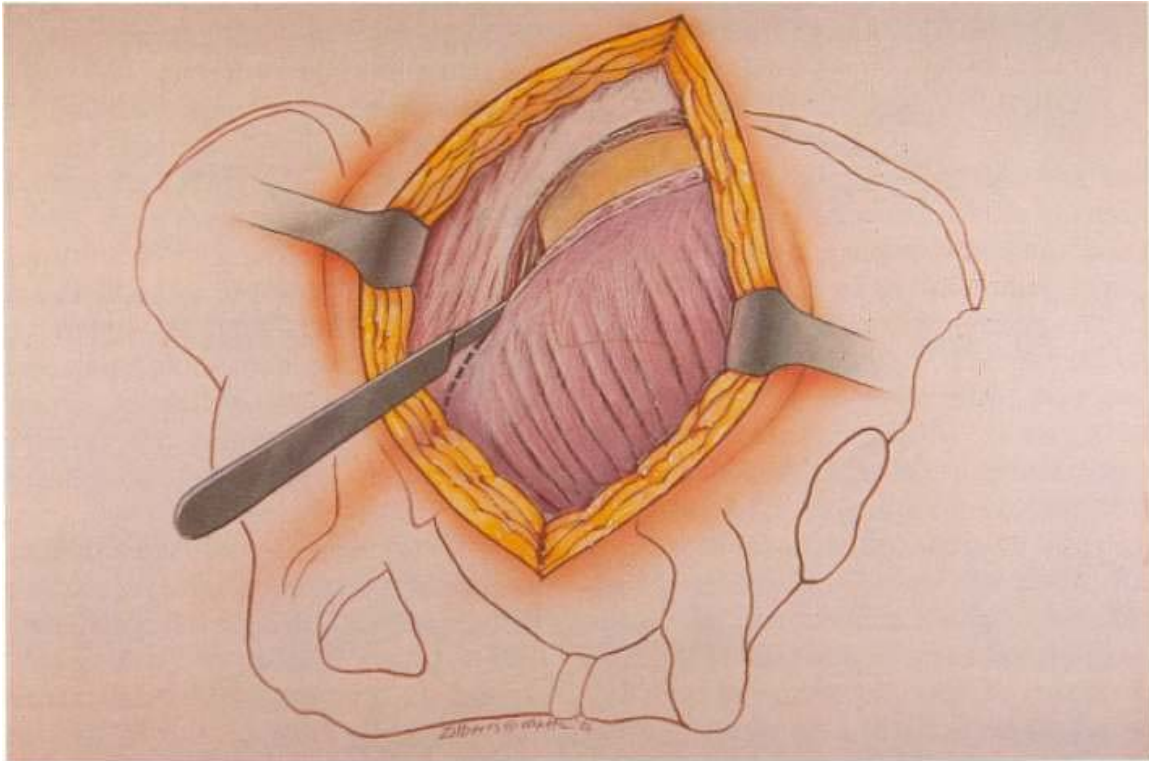


Figure 33. Reflection of the gluteus maximus muscle from the posterior crest and multifidus fascia.

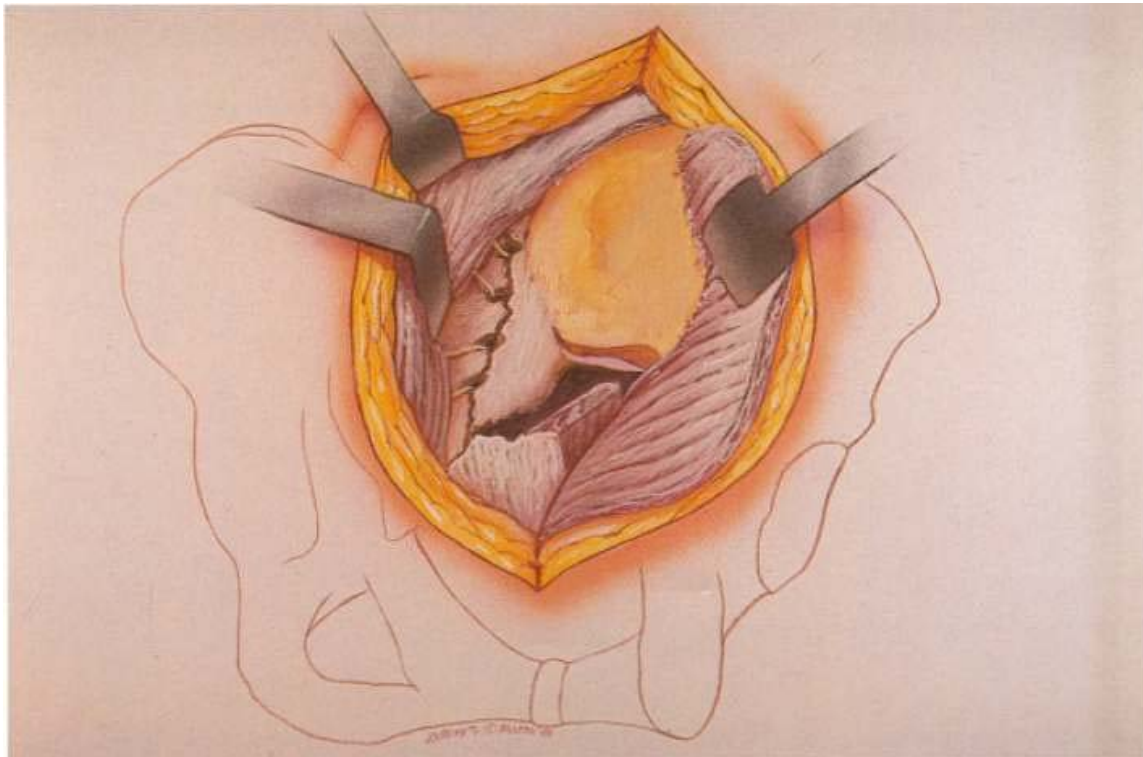


Figure 34. Completed exposure of the posterior ilium, sacroiliac joint and sacrolamina.

With the lateral reflection of the gluteus maximus the greater sciatic notch is exposed.

Further exposure of the notch is obtained by detachment of the piriformis origin and careful elevation along the border of the greater sciatic notch taking care not to injure the superior gluteal vessels or nerve. Exposure of the greater sciatic notch will give a key to the reduction of the sacroiliac joint and also allows a finger to be passed through the notch to palpate the inferior sacroiliac joint anteriorly to the pelvic brim. A sacrum fracture may also be palpated as it traverses the anterior surface of the sacrum. The sacral foramina are palpable as well as the sacral nerve roots as they exit the foramina.

If a sacrum fracture is present, it is necessary to expose the fracture line as it traverses the posterior sacral lamina. This is done by elevating the multifidus muscles from the posterior aspect of the sacrum in a lateral to medial direction starting at the lateral edge of the sacrum. There are small nerve branches that exit through the posterior sacral foramina that supply some sensation to the skin overlying the sacrum, and additionally enervate the multifidus muscles. These can usually be preserved even when the sacral foramina are exposed posteriorly. However if they are sacrificed the resulting disability is negligible (Figure 34). Although not necessary in the majority of cases, it is possible to obtain palpation access to the internal iliac fossa and anterior aspect of the sacroiliac joint by releasing the erector spini muscles and abdominal muscles from the superior portion of the crest, and placing a finger over the top of the crest into the internal iliac fossa.

At the completion of the operation, Hemovac drains should be placed along the lateral ilium and into the greater sciatic notch. The internal iliac fossa should also be drained if it has been exposed. The closure is simple with reapproximation of the gluteal fascia overlying the multifidus and erector spini muscles.

ANTERIOR APPROACH TO THE SACROILIAC JOINT

An alternative exposure to the sacroiliac joint is anterior. For this approach the patient is positioned supine on the PROfx® Surgery Table with the auxiliary Radiolucent Imaging Top attached and centered over a 1.5 meter radiolucent section that is free from obstacles that would impede movement of the image intensifier (Figures 35 & 36) The incision starts just distal to the anterior-superior iliac spine and proceeds posteriorly along the crest about two-thirds of the way along the crest. The periosteum is sharply incised. The abdominal muscles are released from the crest and the iliacus dissected subperiosteally from the internal iliac fossa. The iliacus should be elevated to the pelvic brim distally and the sacroiliac joint more proximally. It is necessary to dissect subperiosteally along the anterior aspect of the sacral ala, however one should be cautious with too vigorous medial dissection because the L5 nerve root crosses the anterior sacral ala and can suffer a stretch injury. The tip of a thin Hohmann retractor is typically driven into the anterior sacral ala about 15 millimeters medial to the sacroiliac joint and another Hohmann retractor is used for retraction over the proximal pelvic brim. The anterior sacroiliac joint is thereby visualized for reduction.



Figure 35. PROfx® Pelvic Reconstruction Orthopedic Fracture Table shown with the auxiliary Radiolucent Imaging Top attached for positioning patient prone for the Approach to the Posterior Pelvic Ring or supine for the Anterior Approach to the Sacroiliac Joint.



Figure 36. PROfx® Pelvic Reconstruction Orthopedic Fracture Table shown with the auxiliary Radiolucent Imaging Top and Leg Spars attached for positioning patient prone for the Approach to the Posterior Pelvic Ring or supine for the Anterior Approach to the Sacroiliac Joint for when the use of traction is desired.

THE APPROACH TO THE ILIAC WING

For isolated fractures of the iliac wing the patient may be positioned either lateral or supine on the PROfx® Surgery Table. The incision parallels the iliac crest. The periosteum is sharply incised along the superior aspect of the crest and from this point the external or internal aspect of the wing may be exposed by elevation of the gluteal muscles or iliacus or both as is found necessary for reduction and fixation.

POSTOPERATIVE CARE

Prophylactic antibiotic which is started preoperatively is continued for 72 hours following the operation. Hemovac drains are normally kept in place for 48 hours though this may be extended to 72 hours with continued drainage. The patient is kept at bed rest until he or she is relatively comfortable, and then is allowed to ambulate with crutches. Weight bearing is limited to the affected side for eight weeks after the operation and then weight bearing as tolerated is instituted. If bilateral injuries requiring internal fixation are present, the patient is allowed to do standing pivot transfers from bed to wheelchair initially and gait training with full weight bearing is started at eight weeks after surgery.

Physical therapy is directed toward muscle strengthening at the hips and in particular strengthening of the abductor musculature. No Ectopic bone prophylaxis is necessary.

THANKS TO EMILE

I would like to express my sincerest gratitude and admiration for Professor Emile Letournel who contributed to the development of all of these surgical approaches and has spent countless hours teaching surgery of the acetabulum and pelvis to myself and other surgeons.

For more information, contact:

Joel M. Matta, MD, Inc.

Orthopaedic Surgery Pelvis and Hip
Reconstruction

2001 Santa Monica Blvd., #1090

Santa Monica, CA 90404

Tel: 310-582-7475

Fax: 310-582-7481

www.hipandpelvis.com

www.newhipnews.com

Email: info@hipandpelvis.com



Surgical Approaches to Fractures of the Acetabulum and Pelvis

For more information, contact:

Joel M. Matta, MD, Inc.

Orthopaedic Surgery Pelvis and Hip Reconstruction

2001 Santa Monica Blvd., #1090

Santa Monica, CA 90404

Tel: 310-582-7475

Fax: 310-582-7481

www.hipandpelvis.com

www.newhipnews.com

Email: info@hipandpelvis.com



Mizuho OSI

30031 Ahern Avenue

Union City, CA 94587-1234 / USA

Telephone: 510-429-1500

Toll Free: 800-777-4674

Outside USA: +1-510-429-1500

Fax: 510-429-8500

www.mizuhosi.com

www.newhipnews.com

PROfx® is a registered trademark of Mizuho OSI. Protected by US patent #7,842,353 B2; European patent #1799161; Korean Patent #10-1247544; Australian patent #2005282927; Canadian patent #2578462; Japanese patent #486493; Other patents pending.